




Scientific Committee on Emerging and Newly Identified Health Risks

SCENIHR

Opinion on

The safety of Metal-on-Metal joint replacements
with a particular focus on hip implants



SCENIHR adopted this Opinion at the 7th plenary of 24-25 September 2014

About the Scientific Committees

Three independent non-food Scientific Committees provide the Commission with the scientific advice it needs when preparing policy and proposals relating to consumer safety, public health and the environment. The Committees also draw the Commission's attention to the new or emerging problems which may pose an actual or potential threat.

These Committees are: the Scientific Committee on Consumer Safety (SCCS), the Scientific Committee on Health and Environmental Risks (SCHER) and the Scientific Committee on Emerging and Newly Identified Health Risks (SCENIHR).

In addition, the Commission relies upon the work of the European Food Safety Authority (EFSA), the European Medicines Agency (EMA), the European Centre for Disease prevention and Control (ECDC) and the European Chemicals Agency (ECHA).

SCENIHR

This Committee deals with questions related to emerging or newly identified health and environmental risks and on broad, complex or multidisciplinary issues requiring a comprehensive assessment of risks to consumer safety or public health and related issues not covered by other Community risk assessment bodies. Examples of potential areas of activity include potential risks associated with interaction of risk factors, synergic effects, cumulative effects, antimicrobial resistance, new technologies such as nanotechnologies, medical devices including those incorporating substances of animal and/or human origin, tissue engineering, blood products, fertility reduction, cancer of endocrine organs, physical hazards such as noise and electromagnetic fields (from mobile phones, transmitters and electronically controlled home environments), and methodologies for assessing new risks. It may also be invited to address risks related to public health determinants and non-transmissible diseases.

Scientific Committee members

Michelle Epstein, Igor Emri, Philippe Hartemann, Peter Hoet, Norbert Leitgeb, Luis Martínez Martínez, Ana Proykova, Luigi Rizzo, Eduardo Rodriguez-Farré, Lesley Rushton, Konrad Rydzynski, Theodoros Samaras, Emanuela Testai, Theo Vermeire

Contact:

European Commission
DG Health & Consumers
Directorate C: Public Health
Unit C2 – Health Information
Office: HTC 03/073 L-2920 Luxembourg

SANCO-C2-SCENIHR@ec.europa.eu

© European Union, 2014
ISSN 1831-4783
10.2772/76284

ISBN 978-92-79-30135-3
ND-AS-13-005-EN-N

The opinions of the Scientific Committees present the views of the independent scientists who are members of the committees. They do not necessarily reflect the views of the European Commission. The opinions are published by the European Commission in their original language only.

http://ec.europa.eu/health/scientific_committees/policy/index_en.htm

ACKNOWLEDGMENTS

The members of the Working Group are acknowledged for their valuable contribution to this opinion. They are:

SCENIHR members:

Prof. Igor EMRI (SI-Ljubljana) - Center for Experimental Mechanics, Faculty of Mechanical Engineering, University of Ljubljana, Slovenia.

Prof. Peter HOET (BE – Leuven) - Department of Public Health, Faculty of Medicine, Experimental Toxicology Unit, Laboratory of Pneumology, Leuven – Belgium (chair of the Working Group since April 2013).

External experts:

Dr Charles Patrick CASE (GB-Bristol) - University of Bristol, United Kingdom.

Prof Wolfgang DEKANT (DE – Wuerzburg) - Department of Toxicology, University of Würzburg, Germany.

Dr Wim DE JONG (NL – Houten) - Department for Product Safety Centre for Health Protection, National Institute for Public Health and the Environment, Bilthoven, The Netherlands.

Prof Klaus-Peter GÜNTHER (DE-Dresden) - Chairman and Director University Center of Orthopaedics and Traumatology, University Hospital Carl Gustav Carus Dresden, Technische Universität Dresden, Germany (Rapporteur).

Prof Arne HENSTEN (NO – Tromsø) - UiT The Arctic University of Norway, Tromsø, Norway (chair of the Working Group until March 2013 and rapporteur).

Prof Dr Habil. Michael MORLOCK (DE-Hamburg) - Director, Institute of Biomechanics, Director, Hamburg Research Centre for Medical Technology FMTHH, TUHH Hamburg University of Technology, Germany.

Dr Susanna STEA (IT-Bologna) - Medical Technology Laboratory, Istituto Ortopedico Rizzoli, Bologna, Itali.

Dr Catherine VAN DER STRAETEN (BE-Sint-Martens-Latem) - Director of Research, Department Orthopaedics and Traumatology, Ghent University Hospital, Belgium.

Dr Cees VERHEYEN (NL-Zwolle) - Dept orthopedic surgery and traumatology Isala Hospital, the Netherlands.

Prof Dr Luigi ZAGRA (IT-Milan) - Istituto Ortopedico Galeazzi IRCCS, Milan, Italy.

Special acknowledgement goes to Prof Dr Michael MORLOCK and Prof Klaus-Peter GÜNTHER for the use of the photographs in this opinion.

All Declarations of Working Group members and supporting experts are available at the following webpage:

http://ec.europa.eu/health/scientific_committees/emerging/members_wg/index_en.htm

ABSTRACT

The European Commission asked the SCENIHR for a scientific opinion to assess the safety of Metal-on-Metal joint replacements with a particular focus on hip implants.

There are two commonly used types of total hip arthroplasty (THA) (i) "stemmed" implants consisting of a ball head (either small-head diameter < 36 mm or large-head diameter ≥ 36 mm), which replaces the entire femoral head, connected to a stem embedded in the femur as well as a cup embedded in the acetabulum. If both head and cup are metal, the implant is called "metal-on-metal" (MoM) total hip arthroplasty; (ii) "hip resurfacing arthroplasty" (HRA) in which the femoral head is resurfaced without a stem and a cup embedded in the acetabulum; both components in HRA consist of metal alloys and are always large diameter.

All types of MoM hip arthroplasties release metals in terms of particles, ions and/or metallo-organic compounds. The deposition of these substances in body fluids and tissue may lead to local and/or systemic adverse health effects. MoM implants with large diameters (large-head MoM THA and HRA) show the highest incidence of local reactions. For systemic health effects, no association with the type of implant or diameter has been established. Local as well as systemic adverse effects can also occur with other types of metallic implants (e.g. plates, screws).

Local tissue reactions: The local responses comprise a broad clinical spectrum ranging from small asymptomatic tissue lesions to severe destruction of bone and soft tissues and include metallosis, aseptic lymphocytic vasculitis associated lesions, pseudotumours and adverse reactions to metal debris. These local responses can occur at any time after surgery (short, medium and long term).

Systemic adverse responses: The toxicity of several metals present in implants has been evaluated in experimental and epidemiological studies. Extrapolation of these data to evaluation of metal particles, ions, and metallo-organic compounds released at the site of the implant and distributed into lymph nodes, bone marrow and internal organs is currently limited because the degradation products are not adequately characterised. There are some specific concerns related to the possible systemic exposure to cobalt and/or chromium after MoM-hip arthroplasty, such as systemic organ toxicity, carcinogenicity and teratogenicity.

There have been a few studies of carcinogenicity but with no consistent evidence of an overall increase in cancer associated with MoM HRA although there has been occasional reported elevation of hematopoietic malignancy, prostate cancer and melanoma rates.

Transplacental passage of metal ions has been demonstrated although without any teratogenic effect up to now.

The SCENIHR concludes that critical values for systemic effects are not yet established for patients after MoM implantation because of the lack of data and it is thus not possible to provide indications on limit values for the metals in any forms.

The SCENIHR decided to adopt the strategy as outlined in the European Consensus Statement, which includes recommendations on technical issues (e.g. metal ion determination for screening purposes should be performed in whole blood), determination of critical threshold ranges (e.g. for Co a range of 2 to 7 µg/L Co whole blood) and systematic follow-up for all patients and all implants due to the risks of MoM bearings.

Overall, the choice of the type of implant should be based on a detailed case-by-case evaluation taking into account risks and benefits relating to the characteristics of each patient such as age, gender, physical activity, occupation etc.

The experience with MoM implants to date indicates that introduction of new or technically modified implants on the market should be made step-by-step. It is stressed that suitable preclinical and clinical studies are particularly important and that MoM implants requires close and comprehensive post-market surveillance. Further research is needed including appropriate toxicological studies using comparable routes of exposure to humans, prospective human studies with adequate exposure and outcome data and post-mortem studies. National registries of MoM HRA patients are recommended with follow-up for local, systemic and long-term effects

Keywords: Total hip arthroplasty, hip resurfacing, metal-on-metal, metal ions, metal debris, health effects, adverse reaction, pseudotumours, ALVAL, ARMD

Opinion to be cited as:

SCENIHR (Scientific Committee on Emerging and Newly Identified Health Risks), the safety of Metal-on-Metal joint replacements with a particular focus on hip implants, 25 September 2014

TABLE OF CONTENTS

| | |
|---|----|
| ABSTRACT..... | 4 |
| 1. EXECUTIVE SUMMARY | 8 |
| 2. BACKGROUND | 10 |
| 3. TERMS OF REFERENCE | 11 |
| 4. SCIENTIFIC RATIONALE | 12 |
| 4.1. Introduction..... | 12 |
| 4.2. Metal-on-Metal implants | 13 |
| 4.2.1. Categories of Metal-on-Metal implants..... | 13 |
| 4.2.1.1. Metal-on-metal THA..... | 14 |
| <i>Small-head MoM THA:</i> | 14 |
| <i>Large-head MoM THA:</i> | 14 |
| 4.2.1.2. Hip resurfacing (HRA) | 14 |
| 4.2.2. Metal wear and degradation products | 15 |
| 4.3. Clinical outcomes..... | 15 |
| 4.3.1 Survival rates of MoM-THA..... | 15 |
| 4.3.1.1. Small-head MoM THA..... | 16 |
| 4.3.1.2. Large-head MoM THA..... | 16 |
| 4.3.1.3. Hip resurfacing arthroplasty (HRA) | 17 |
| 4.3.2. Clinical function and Quality-of-Life after MoM implantation | 18 |
| 4.3.3. Potential adverse effects (local and systemic) of MoM implants in comparison to non-MoM implants..... | 19 |
| 4.3.3.1. Local adverse effects | 19 |
| 4.3.3.2. Systemic adverse effects | 20 |
| 4.3.4. Factors influencing the outcome: surgeon, patient and implant | 24 |
| 4.3.5. Conclusions | 25 |
| 4.4. Diagnostic tools needed for clinical decision-making..... | 25 |
| 4.4.1. Imaging studies | 25 |
| 4.4.1.1. Radiographic imaging..... | 26 |
| 4.4.1.2. Ultrasound (US) examination | 26 |
| 4.4.1.3. Computed tomography (CT)..... | 26 |
| 4.4.1.4. Magnetic resonance imaging (MRI) | 27 |
| 4.4.2. Measurements of metal/metal ions in body fluids | 27 |

| | |
|---|----|
| 4.4.2.1. Sample sources | 27 |
| 4.4.2.2. Protocol for blood sampling..... | 28 |
| 4.4.2.3. Interpretation of metal ion levels..... | 28 |
| 4.4.3. Possibility for analysis of synovial fluid and periprosthetic tissue..... | 29 |
| 4.4.4. Conclusions | 29 |
| 4.5. Metal toxicology | 30 |
| 4.6. Clinical strategies for the management of patients with implanted MoM | 31 |
| 4.6.1. Recent opinions and comments..... | 31 |
| 4.6.2. European multidisciplinary consensus statement on the use and monitoring of metal-on-metal bearings for THA and HRA | 34 |
| 4.6.3. Results of MoM implant revision surgery | 35 |
| 4.6.4. Conclusions | 36 |
| 4.7. Conclusions of MoM implants..... | 37 |
| 4.7.1. Risk factors for MoM implants | 37 |
| 4.7.2. Benefit factors for MoM implants | 37 |
| 4.7.3. Follow-up of MoM implants and induced adverse effects..... | 37 |
| 4.7.4. Gaps in knowledge..... | 38 |
| 4.8. Research recommendations..... | 39 |
| 5. OPINION | 41 |
| 6. CONSIDERATION OF THE RESPONSES RECEIVED DURING THE CONSULTATION PROCESS | 44 |
| 7. MINORITY OPINION | 44 |
| 8. LIST OF ABBREVIATIONS | 45 |
| 9. REFERENCES | 46 |
| Appendix 1: Detailed description of Metal-on-Metal implants | 57 |
| Appendix 2: Selected recommendations for the management of patients with implanted MoM hip arthroplasties from national health authorities and scientific organisations | 62 |

1. EXECUTIVE SUMMARY

SCENIHR was requested to provide an opinion on the following: 1) To determine the short-, medium- and long-term local and systemic health effects caused by metal particles, metal ions, and metallo-organic compounds resulting from the implanted medical device and if possible to provide indications on limit values for the metals in any forms, 2) To advise on the predictive value of metal ions in body fluids, clinical strategies and other aspects needed to ensure the safety of implanted patients. Criteria that should inform the medical decision with respect to the implanted patient should be identified where possible, 3) To identify criteria regarding the safety and safe use of MoM implants used in arthroplasty, paying special attention to design and patient groups, and 4) Where relevant to identify needs for further research.

In response to the issue of short, medium and long term local and systemic health effects caused by metal particles, metal ions, metallo-organic compounds resulting from the implanted medical device, we summarise that Metal-on-Metal (MoM) hip arthroplasty leads to a release of metal products (e.g. particles and ions) which can in addition form metallo-organic compounds in the body. These products can be deposited in draining lymph nodes and internal organs and may result in local and systemic adverse health effects. However, it is not possible to determine whether these are due to metal particles, ions or metallo-organic compounds released from the implants.

Local responses consist of a broad clinical spectrum ranging from small asymptomatic tissue lesions to severe destruction of bone and soft tissues, which are designated as: metallosis, ALVAL (aseptic lymphocytic vasculitis associated lesion), pseudotumours and ARMD (adverse reactions to metal debris) and may occur short-, medium- and long-term post-operatively. Based on follow-up studies, a threshold value for clinical concern is expected to be within the range of 2 to 7 µg/L (exact levels have still to be determined within this range).

Animal and occupational toxicology studies for evaluating adverse effects of metals in patients with MoM hip arthroplasties are currently limited because the degradation products are not adequately characterised. Therefore, the observations in various animal studies cannot be extrapolated to the internal exposure by the release of metals from MoM implants. Specific concerns related to possible systemic exposure to cobalt and/or chromium after MoM-hip arthroplasty include systemic organ toxicity, carcinogenicity and teratogenicity, but the evidence is insufficient and further confirmation is needed. Additionally, transplacental passage of metal ions has been demonstrated in the absence of teratogenic effect. There is no distinction between short-, medium- and long-term systemic effects.

These adverse health effects apply to all types of these MoM hip arthroplasties including Total Hip Arthroplasty THA with either small (head diameter < 36 mm) or large-heads (head diameter ≥ 36 mm) and Resurfacing Hip Arthroplasty (HR, always large-head diameter). However, MoM arthroplasty with large diameters (resurfacing and especially large-head MoM THA) are associated with the highest incidence of local reactions. Remarkably, systemic health effects have not been associated with the type of implant or diameter. Local and systemic adverse effects may also occur with other types of metallic implants (e.g. plates, screws).

We conclude that critical values for systemic effects are not yet established for patients after MoM implantation because of the lack of data and therefore, it is not possible to provide indications on limit values for the metals in any forms.

In response to the request for advise on the predictive value of metal ions in body fluids, clinical strategies and other aspects needed to ensure the safety of implanted patients and criteria that should inform the medical decision with respect to the implanted patient should be identified where possible, we conclude that based on current information, no exact values of critical metal ions thresholds are available for clinical decision-making regarding clinical follow-up. The SCENIHR decided to adopt the strategy as outlined in the European Consensus Statement, which includes recommendations on technical issues (e.g. metal ion determination for screening purposes should be performed in whole blood), determination of critical threshold

ranges (e.g. for Co a range of 2 to 7 µg/L Co whole blood) and systematic follow-up for all patients and all implants due to the risks of MoM bearings.

For small-head MoM THA, a systematic follow-up comparable to conventional THA is sufficient. For large-head MoM implants, an annual follow-up for the life of the joint is recommended. For the HRA, an annual follow-up for the first five years is recommended, which may be changed to local protocols for patients with conventional THA, if metal ion levels are not significantly elevated. HRA-patients with special risk factors like small component size, female gender, low coverage arc should have an annual follow-up for the lifetime of the joint.

All patients should undergo clinical and radiographic examination during follow-up. Metal ion determination is recommended for large-head MoM THA on a routine basis and for HRA patients, in the first postoperative years and thereafter depending on their clinical performance. In the case of clinical and/or radiographic abnormalities and metal ion values above the range of 2 to 7 µg/L of Cobalt, ultrasound, CT-scan, and/or MARS-MRI are recommended. Metal ion screening should be performed in whole blood and Cobalt may serve as the reference substance. Importantly, these recommendations are based on potential local adverse effects of MoM arthroplasties, because critical values for systemic effects are not known.

In response to identifying criteria regarding the safety and safe use of MoM implants used in arthroplasty, paying special attention to design and patient groups, we conclude that the application of MoM hip arthroplasty should be carefully considered on a case-by-case basis, due to the potential adverse effects of released metal, especially in certain subgroups of patients. For example, all types of MoM implants are contraindicated in females of childbearing age and in patients who are allergic to relevant metals. Additionally, MoM HRA should not be performed in females with small femoral head size. However, in carefully selected young, active male patients with large femoral head size and favourable large head-neck-ratio, HRA may be an alternative to conventional THA. The choice of implant type should be based on a detailed case-by-case evaluation, which takes into account all risks and benefits. Lastly, very experienced surgeons should perform the surgical procedure to minimise the risk of incorrect positioning.

MoM experience indicates a stepwise introduction of new implants types, even if similar to those in use in the market, accompanied by pre-clinical and clinical studies. The regulatory approval by the Notified Bodies in Europe should not be based on the acceptance of minimal design changes.

Further research is necessary in the following areas: 1) For additional safety evaluation, it is necessary to obtain data on internal exposure in animal toxicity studies for comparison with exposures occurring in patients who received MoM arthroplasty, 2) It is necessary to clarify which components of metallic debris are responsible for the local and/or systemic adverse reactions, 3) It is necessary to investigate the contribution of the bearing and the taper interface to the production of metallic debris as well as a focus on the taper interface that includes other bearing articulations. 4) Prospective studies to determine the relationship between patients metal levels and clinical outcome including standardised reliable methodology for metal determination, 5) Local and systemic reactions should be investigated in post-mortem samples including determination of metals and their various combinations, 6) Determination of the possible role of metals other than Co and Cr such as Ti and V is necessary, because of the inconsistent relationship between the clinical outcome and Co/Cr metal ion levels. Additionally, research is needed to replace metals with other "hard", stable and low hazardous materials. 7) Determine the incidence and prevalence of adverse local and systemic health effects in patients with MoM hip arthroplasties by setting up mandatory national registries, which should be applied to all permanent implants.

2. BACKGROUND

A specific category of implants are those used for hip arthroplasty. This treatment is very successful in recovering unrestrained and pain free mobility in patients suffering from diseases such as advanced osteoarthritis, which accounts for about two thirds of all total hip replacements.

A preliminary evaluation indicates that the total number of European patients implanted with Metal-on-Metal hip replacements is above 100.000¹. Given the extensive use of these implants, considerable effort was put into increasing their life span. Since first-generation implants with Metal-on-Metal (MoM) as well as with conventional polyethylene (MoP) bearing articulation demonstrated problems with durability (aseptic loosening due to wear particles is the most frequent reason for revision), alternative hard and soft articulating surfaces were developed to decrease wear. These newer articulating surfaces were engineered from improved materials in optimised designs. Second- and third-generation MoM hip implants, for example, made use of these new joints.

MoM hip replacements offer the potential to decrease wear, but pose additional challenges such as a potential for an increased release of metal particles or ions, including cobalt and chromium. This metal debris can originate either from the bearing articulation directly or from the modular taper junction between prosthesis head and stem. In the past, the taper has only been reported anecdotally as the origin of problems. Recently, the taper has emerged as the focus of attention, since large modular metal heads for MoM arthroplasty were introduced due to their ability to reduce dislocation risk, which is the second major complication in hip arthroplasty. These larger heads, however, put larger loads on the taper junction and are suspected to be responsible for the problems suddenly occurring at this side.

Co and Cr are known to be toxic under specific circumstances. The health implications remain unclear, but concerns related to hypersensitivity reaction and subsequent osteolysis, T-cell infiltration and pseudotumour have been raised in a number of recent scientific publications. Long-term effects are still not fully assessed, especially in terms of carcinogenicity, genotoxicity and reproductive toxicity.

Besides their use in hip arthroplasty, metal alloy implants have been used successfully in orthopaedics for years, for example in knee operations and fracture repair. All metal implants are known to release metal ions due to corrosive processes, but some MoM prostheses do so to a much greater extent than previously thought. In the case of total knee arthroplasty, large metal surface areas are present, leading to the possibility of increased release of metal ions.

¹ Based on data from FR, PT, DK, NO, NL, DE, AT, CZ, FI, CH, ES (mainly sales figures)

3. TERMS OF REFERENCE

In the light of the above considerations, the Scientific Committee on Emerging and Newly Identified Health Risks is requested to provide a scientific opinion on 'The safety of Metal-on-Metal joint replacements with a particular focus on hip implants'.

In particular, the SCENIHR is asked:

1. To determine the short-, medium- and long-term local and systemic health effects caused by metal particles, metal ions, and metallo-organic compounds resulting from the implanted medical device and if possible to provide indications on limit values for the metals in any forms.
2. To advise on the predictive value of metal ions in body fluids, clinical strategies and other aspects needed to ensure the safety of implanted patients. Criteria that should inform the medical decision with respect to the implanted patient should be identified where possible.
3. To identify criteria regarding the safety and safe use of MoM implants used in arthroplasty, paying special attention to design and patient groups.
4. Where relevant to identify needs for further research.

4. SCIENTIFIC RATIONALE

4.1. Introduction

In this opinion, total hip arthroplasty (THA) with a "stemmed" implant refers to a modular implant system which replaces the entire femoral head and is fixed by a stem embedded in the femur as well as with a cup embedded in the acetabulum. The cup can consist of a single shell (mostly polyethylene) or a titanium backside together with an articulating insert (made of polyethylene, metal or ceramic). The replaced head, which may be metal or ceramic, is usually connected to the stem in a modular way with a taper/trunnion. In contrast, the term "hip resurfacing arthroplasty" (HRA) indicates a total hip arthroplasty which simply resurfaces the femoral head and the acetabulum. In addition, it may have a peg (stem) in the femoral neck. The fixation of the hip implants to the bone can be achieved with or without cement.

If the articulating surfaces of stemmed THA consist of metal, the implant is called a metal-on-metal (MoM) total hip arthroplasty. Since in all contemporary HRA procedures the head as well as the cup consists of metal alloys, they are by definition MoM implants as well. MoM hip implants were first put into use in the early 1960s. Following the introduction of polyethylene, the use of the MoM implants largely stopped, but at the end of 1980s, MoM implants were reintroduced as a bearing surface for hip arthroplasty to solve the problem of particle-induced osteolysis secondary to polyethylene wear. *In vitro* hip-simulator studies demonstrated a substantial decrease in volumetric wear and much smaller particles with MoM compared to MoP implants. This finding was confirmed *in vivo* with high-carbon alloy small-head MoM THA (mostly 28 mm and 32 mm diameter heads). The use of larger-diameter femoral heads (≥ 36 mm) as a solution to postoperative dislocation became possible with alternative bearings such as MoM and ceramic-on-ceramic (CoC) with less apparent wear compared to MoP. Larger heads have effectively reduced the dislocation rate.

Hip resurfacing arthroplasty was introduced with the aim of addressing the inferior survival and unsatisfactory clinical results with THA in young and active patients. Early designs of resurfacing with PE cups did not perform well because of rapid wear. Resurfacing with MoM implants was introduced to address this. It was assumed that the anatomical reconstruction of the joint might lead to a better function and higher activity levels compared to THA. Despite the poor results with certain HRA designs and certain populations, some series from designers, independent groups and arthroplasty registers have shown that in some circumstances resurfacing can produce results similar to those from conventional THA.

MoM large diameter femoral heads (≥ 36 mm) that were similar to the HRA femoral heads, but applicable to a femoral stem via a taper/trunnion connection were first introduced to facilitate HRA revisions for fractured femoral necks. They were subsequently used for primary THA because of the apparent advantage with regard to prevention of dislocation.

To date, approximately 1 million MoM hip prostheses have been implanted worldwide. These implants are typically composed of Cobalt-Chromium-Molybdenum alloys and other materials including titanium alloys. Wear and corrosion of the bearing and taper surfaces generate metal particles and ions, predominantly cobalt (Co) and chromium (Cr). In addition, other materials, like titanium, could be released as well. Bacteriological and clinical studies in hip simulators have described a characteristic wear pattern of MoM hip implants which is initially characterised by a short high-wear running-in period, followed by a lower-wear steady-state. This was clinically only observed for prostheses, which did not show signs of rim loading at revision (Joyce et al., 2011; Morlock et al., 2008)

The generation of metal products might lead to severe local adverse soft-tissue reactions as well as potentially systemic adverse events. In cases of increased wear, high levels of metal particles and ions will be released from the wearing articulating surfaces. Particles and ions can also be released from non-articulating surfaces and implants. The use of blood metal level as surrogate markers of metal release from implants is a well-established method and is now recommended as a screening tool for the in-vivo performance of MoM implants (DeSmet 2008, De Smet 2011, Haddad FS et al. 2011, Heisel et al. 2008, Kwon et al. 2011, Langton et al. 2009, Mac Donald et al. 2004, Smolders et al. 2011). Although smaller diameter (< 36 mm)

MoM total hip replacements and some HRA designs have been successful, multiple recent reports have documented markedly increased Co and Cr concentrations in blood and urine which indicates systemic exposure with poorly functioning MoM hip prostheses (Langton et al. 2010, Langton et al. 2011, Kwon 2010 Matthies 2012, Kwon 2011, Hart 2011, Van Der Straeten 2012). Besides the local tissue destruction, concerns have also been raised about possible consequences of elevated metal levels in the systemic circulation (Oldenburg et al. 2009, Tower 2010, Machado et al. 2012, Sotos and Tower 2013, Zywił et al. 2013, Chen et al. 2013, Prentice et al. 2013).

Arthroplasty registry data have revealed that most Large Diameter (≥ 36 mm) MoM THA implants are associated with a high failure rate (Australian Orthopaedic Association National Joint Replacement Registry 2012, National Joint Registry 2013). This may be due to adverse local tissue reactions to metal debris generated either at the bearing articulation or at the taper/trunnion connection. Some of these failing MoM THA with big femoral heads have been shown to cause severe tissue destruction even without highly elevated Co or Cr levels in the blood. This opinion will focus on the issues associated with MoM hip arthroplasty, because the problems of MoM are found mostly in hip surgery. Other large-head hip implants may also be associated with clinical problems; however, those will not be reviewed in this opinion.

4.2. Metal-on-Metal implants

4.2.1. Categories of Metal-on-Metal implants

A detailed classification of the different materials and types of MoM implants used in hip arthroplasty is given in the Appendix. In this section a short description of the two categories of implants used is given. These are:

- (1) Metal-on-Metal THA:
 - a) Small-head: Modular metal head on a hip stem with a modular metal insert in a metal socket with a head diameter of less than 36 mm (Fig. 1a).
 - b) Large-head: Modular metal head on a hip stem with a metal cup, with a head diameter of 36 mm or more (Fig. 1b).
- (2) Hip Resurfacing (HRA):

Metal resurfacing head with a monobloc metal cup (Fig. 1c)

It should be realised that the discrimination between small-heads (<36 mm) and large-heads (≥ 36 mm) is somewhat arbitrary but it is used in most recent literature including the European Consensus Statement (Günther et al. 2013, Medicines and Healthcare Products Regulatory Agency 2012).




Figure 1: The three groups of contemporary Metal-on-Metal hip joint designs. Left to right: (a) Small-head MoM, (b) Large-head MoM, (c) Resurfacing. The choice of components illustrated is not related to the problems currently observed with certain MoM hip bearing articulations. Manufacturers are therefore not mentioned. Sizes are only examples and represent typical measures. (Source: M. Morlock)

4.2.1.1. Metal-on-metal THA

Small-head MoM THA:

In 1998, second generation MoM bearings began being produced (Metasul™, Sulzer, Switzerland). This design with heads of 28mm and 32mm diameter achieved similar or better clinical success than other bearing materials and is still used today. These bearings are typically used in conjunction with a modular uncemented hip stem and a modular uncemented hip socket.

Large-head MoM THA:

The use of modular metal heads with 36mm diameter and larger is rather recent in MoM arthroplasty. If the head diameter is too large, modular cups are ruled out and monobloc metal cups must be used. Monobloc metal cups are similar to resurfacing cups. This group is the one with the highest reported revision rate, most probably due to issues at the taper connection with large metal heads.

4.2.1.2. Hip resurfacing (HRA)

The revival of resurfacing arthroplasty, after the poor results with the Wagner resurfacing design in the 1970s and 1980s, was driven by Amstutz and McMinn around 1995. Since this time, HR is available only as MoM articulation. After several publications of good short and midterm results, resurfacing became popular very quickly and many companies introduced their own designs into the market. The resurfacing heads are cemented onto a reamed femoral head in most designs; the monobloc cups are used without cement in all designs.

4.2.2. Metal wear and degradation products

Several different metal alloys are used in MoM implants. The bearing surface itself is mostly made from CoCrMo-alloys. They may in addition contain small amounts of nickel (Ni), iron (Fe), manganese (Mn), silicon (Si) and vanadium (V).

MoM implant wear debris may consist of metallic particles produced either by mechanical wear or the products of metal corrosion in the biological environment of the hip joint and surrounding fluid and tissues. In addition, these constituents may dissolve in both intracellular and extracellular solutions, leading to the presence of the ions, which can also be produced directly by corrosion processes (Gill 2011). Presently, it is unknown whether ions, particles or metalloorganic compounds are responsible for the adverse reactions to the different metal alloys.

4.3. Clinical outcomes

In THA, one of the most important influencing factors on the long-term success is the tribology of bearing materials, as wear and corrosion can lead to osteolysis and implant loosening. This phenomenon has been extensively studied in conventional polyethylene cups, which have been the most common implants over decades after the introduction of THA (Willert and Semlitsch 1977). As the survival rates of THA with conventional polyethylene cups in young and active patients have not been very good in the past, several alternatives have been introduced (e.g. MoM, CoC, highly crosslinked polyethylene).

When compared with other articulating surface materials, MoM seem to have several potential advantages (Hannemann et al. 2013):

- There are no polyethylene particles in pure MoM bearings that may cause inflammation and subsequently osteolysis.
- MoM bearings produce less volumetric wear compared to conventional polyethylene.
- There is a reduced risk of fracture in MoM bearings compared to ceramics.
- MoM is currently the only technique for surface replacement.
- Large-head THA (36mm head size and larger) – often used with MoM bearings - as well as hip resurfacing have a reduced risk of dislocation compared to small-head THA (< 36mm head size). In large-head THA, range of motion increases with the head size (only up to 40mm).
- MoM Hip resurfacing allows more preservation of bone stock on the femoral side when compared to conventional THR.

Due to these proposed advantages, MoM implants of different categories (small and large-head MoM THA, HRA) have been developed and are still in clinical use. The clinical outcomes in these categories of MoM implants are very different as summarised in the following chapter.

4.3.1 Survival rates of MoM-THA

An important parameter of success is the survival rate of artificial implants, which can be documented in appropriate clinical studies with adequate long-term follow-up (10 or more years of follow-up) as well as in Arthroplasty Registries. Only a few long-term clinical studies are available for small-head MoM THA and HRA, but increasing data from National Joint Registries especially in the UK and Australia allows a comparison of all three different MoM

implant categories with other THA devices (Australian Orthopaedic Association National Joint Replacement Registry 2012, National Joint Registry for England and Wales 2010, RIPO Register in Emilia-Romagna, Italy 2012).

MoM implants, in general, seem to show lower survival rates in meta-analyses as well as in registries when compared to THA with other bearings. For example, the revision rate of all MoM implants after 11 years in the Australian Registry is 14.1%, while the revision rate for non-MoM-THA is between 5.1 – 9.5 % (Australian Orthopaedic Association National Joint Replacement Registry 2012). The high MoM revision rate, however, is mainly caused by the worse survival rates of large-head hip replacements.

4.3.1.1. Small-head MoM THA

For small-head THA with a head diameter of < 36 mm, the 11-year revision rate in MoM implants (6.0%) is comparable to the revision rate of Ceramic-on-Ceramic (5.8%), Ceramic-on-Polyethylene (9.3% for conventional PE and 5.7% for highly cross-linked PE) as well as MoP (8.9%)(Australian Registry, 2012).

In clinical studies, the results depend on the type of metal bearing: For Metasul® very promising 10-year survival rates of 94 – 98 % (Grubl et al. 2007, Eswaramoorthy et al. 2008, Zenz et al. 2009) are documented. However, Bjorgul et al. (2013) recently reported higher revision rates for aseptic loosening in a randomised study even for Metasul® 28mm heads when compared to ceramic-on-polyethylene bearings. The results of other implants with lower carbide concentrations are significantly worse (Korovessis et al. 2006, Milosev et al. 2006, Park et al. 2005). Repantis et al. (2013) observed a revision rate of 18% twelve years after implantation of a cementless THA with a low-carbide bearing surface. In addition, there are reports describing the development of local adverse reactions to metal debris (Baur et al. 2005, Gruber et al. 2007).

From these investigations, it can be concluded that high-quality MoM bearings with head diameters of < 36 mm show a sufficient 10-year survival rate, which mostly meets current international benchmarks for the performance of modern primary joint replacement. However, metal debris may occur even in asymptomatic patients with small-head MoM implants. Therefore, it would be necessary to perform adequate screening investigations in order to determine the incidence of adverse tissue reactions in patients who have not undergone revision (see 4.3.3.1).

4.3.1.2. Large-head MoM THA

There are no long-term studies available for large-head MoM THA, but high-revision rates even short- and medium-term reports document the poor performance of most implants due to a high incidence of pseudotumour formation. Bosker et al. (2012) report 39% CT-diagnosed pseudotumours in patients with a revision rate of 12%, 3.5 years after implantation of a Magnum/ReCap®-configuration. Mokka et al. (2013) recently performed systematic MRI investigations in a cohort of 77 patients with the same implant and described a 50% rate of ARMD at an average follow-up time of 6.0 (5.5–6.7) years. In the series of Bolland et al. (2011), 31 revisions had to be performed 5 years postoperatively in 185 patients with Adept®-implants or a combination of BHR acetabular components and large femoral heads from the same manufacturer. Langton et al. (2010) describe a revision rate of 6% for ASR®-implants after 3.5 years due to pseudotumours. More recently, the manufacturer of this device projected a 37% revision rate at less than five years and has recalled this product from the market (<http://www.depuuy.com/asr-hip-replacement-recall>). Meyer et al. (2012) described the histological investigation of 114 DUROM®-LDH®-explants, which have been revised in an original series of 650 operated patients (805 hips). They concluded that the high failure rate

may be due to a combination of elevated metal ion release and fretting corrosion at the taper due to the large-head diameter.

Some registries also provide information about the performance of large-head MoM THA: The Australian Registry (Australian Orthopaedic Association National Joint Replacement Registry 2012) showed that the 10-year cumulative percent revision of MoM implants with a head diameter of 36 mm and more is four times higher (20.3%) than the cumulative percent revision of CoC bearings with similar diameter. Recently, Mocca et al. (2013) have extracted data from the Finnish Arthroplasty Register and compared the risk of revision of 8059 cementless LH-MoM THA to that of conventional small-head MoP THA total hip arthroplasties. The 7-year unadjusted Kaplan–Meier survival was 96% (95% CI = 95–97) for large diameter MoM THA and 95% (95% CI = 95–96) for conventional THA. Although there was no significant difference in overall revision risks between MoM and conventional implants, in-depth analyses revealed increased revision rates for LH-MoM in female patients aged 55 years or above as well as for individual implants. An identical observation of higher revision rates of LH-MoM implants with increasing age as well as an influence of the type of implant can be observed in the National Joint Registry of England and Wales (National Joint Registry, 2012).

4.3.1.3. Hip resurfacing arthroplasty (HRA)

Van der Wegen et al. (2011) performed a meta-analysis and identified a HRA survival of 84% to 100% in 29 articles (10,621 resurfaced hips) with a mean follow-up from 0.6 to 10.5 years. According to their data, none of the implants met the full ten-year National Institute of Clinical Excellence (NICE) benchmark, which is a survival rate of 90% at a follow-up of ten years. In contrast, Sehatzadeh et al. (2012) stated in a more recently performed Ontario Health Technology Assessment with analysis of six different implants that available revision rates for HRA with three implants (BHR®, ConservePlus®, and Cormet®) met the NICE criteria. Two implants had only short-term follow-ups (Re-Cap®, DUROM®) and resurfacing with one of the implants (ASR®) failed to meet the NICE criteria.

The Canadian Arthroplasty Society (2013) recently reported survival rates in a retrospective cohort study involving 2773 HRA at 11 centres. Kaplan–Meier survival analysis showed a cumulative survival of 96.4% (95% confidence interval (CI) 96.1 to 96.9) at five years. The results were superior for male patients (97.4% 5-year survival; 95% CI 97.1 to 97.7) when compared to female patients (93.6% 5-year survival; 95% CI 92.6 to 94.6). The most common cause of failure was fracture of the femoral neck, followed by loosening of the femoral component.

Subsequently, long-term studies with a follow-up of at least 10 years have been published with survival rates of 87.0 - 95.5% (Amstutz et al. 2010, Daniel et al. 2010, Treacy et al. 2011, Hartmann et al. 2012). One recent study reports an overall cumulative survival of 94.1% (95% CI 84.9 to 97.3) at 14-year follow-up in patients under the age of 50 years who had received a BHR® HRA (Matharu et al. 2013). Murray et al. (2013) observed a ten-year survival of 95% (95% CI 92.0 to 97.4) in male patients after implantation of the BHR®. In female patients, however, the ten-year survival was only 74% (95% CI 83 to 91). Mean age of the total cohort at surgery was 51.9 years (16.5 to 81.5).

In most Arthroplasty Registries, however, the survival rates for HRA are generally lower when compared to stemmed THA. Five years postoperatively, the prosthesis survival in the English Registry (National Joint replacement Registry 2010) is 94% for HRA and 96 – 99% for conventional THA. The Australian revision rates 11 years postoperatively are 9,5% for HRA and 7,2% for conventional THA (Australian Orthopaedic Association National Joint Replacement Registry 2012). Survival rates listed in a regional Italian registry at 8 years is 91.5% for HRA and 95.3% for conventional THA (RIPO Register 2012).

Detailed analyses from the Australian Arthroplasty Registry data clearly demonstrate an influence of gender as well as type and size of the implant on the survival rate (Australian Arthroplasty Register 2010 and 2012) : The 7-year-revision rate in female patients (16.9%) is

three times higher than the revision rate in male patients (6.1%). The revision rate for BHR®-resurfacing (5.1%) is similar to conventional THA and significantly lower than the revision rate for the ASR®-prosthesis (23.4 %) as the implant with the worst performance. The 10-year revision rate for HRA with femoral head size ≥ 50 mm is below 5%, while implants with a head size ≤ 49 mm show a 12% revision rate.

In summary, the current survival rates of HRA are generally lower than in conventional implants, but comparable results may be achieved in young male patients with a well-performing type of implant and sufficient head size as well as correct positioning. Most investigations on prosthesis survival do not take into account, however, the potential of local adverse tissue reactions from metal debris, which can arise even in well performing implants.

4.3.2. Clinical function and Quality-of-Life after MoM implantation

Due to “anatomical” restoration of the hip joint, an improvement of clinical function and Quality-of-Life over conventional THA has been postulated for hip resurfacing in the past. Shimmin and Bare (2011) have indeed shown in a meta-analysis that HRA provides equivalent, if not better functional outcomes in well selected patients (young and active male patients). They highlight, however, that a reported short- to medium-term trend towards superior function and patient satisfaction after HRA, which can be demonstrated in many observational studies, may disappear after matching for age, gender and preoperative function.

Only a few randomised trials exist, where a direct comparison of HRA and conventional THA has been performed. Vendittoli et al. (2010), for example, have shown that at 1 and 2 years post-operatively, patients with HRA achieved statistically significantly better functional scores. However, differences in scores were of slight clinical relevance. Aqil et al. (2013) recently demonstrated in a single-blinded controlled study that HRA more closely approximated the gait of the normal control group than THA. Other groups also reported more normal hip kinematics and functionality in HRA (Mont 2007, Benedetti 2012, Shrader 2009), while Petersen et al. (2011) did not find any relevant difference to THA in a randomised controlled trial.

For stemmed large-head implants, early reports confirmed the proposed advantages of increased range of motion and lower risk of dislocation due to the increased head diameter on a small neck (Cuckler et al. 2004, Sikes et al. 2008, Engh et al. 2010 Ball ST 2007, Garbuz 2010). However, recent information on poor performances, as stated in the papers above, negates the early suggestions for advantages for these implants. In addition, one recently published study (Zagra et al. 2013) shows no difference in gait recovery comparing large-head to small-head implants by means of gait analysis.

There are no studies available where either a superior clinical function or better Quality-of-Life has been documented in a direct comparison of small-head THA with MoM bearing versus conventional bearings.

While clinical function after MoM THR has been documented in most studies regarding HRA, only a few investigations looked at appropriate health-related QoL measures. Lingard et al. (2009) reported a significantly greater QoL-improvement in 132 patients with HRA, compared to 214 patients with stemmed THA, one year postoperatively.

In summary, there is no general superior clinical function and no better QoL after implantation of a MoM hip replacement compared to THA with non-MoM-bearings. Subgroups of patients (young and active men), however, may show superior short- to medium-term clinical outcomes after HRA.

4.3.3. Potential adverse effects (local and systemic) of MoM implants in comparison to non-MoM implants

Potential adverse effects of MoM-THR can be the unspecific risks every patient undergoes with an arthroplasty procedure (i.e. thrombosis, wound infection, etc.) as well as specific risks due to metal exposure (Keegan 2007). As MoM-THA leads to a release of metallic products (i.e. particles, ions, metallo-organic compounds) into body fluids, an accumulation in lymph nodes, bone marrow and internal organs is possible. Local adverse effects (characteristic histopathological response to particles) as well as systemic adverse effects (toxicity, carcinogenicity and teratogenicity) are possible. There is also an ongoing discussion about the potential of orthopaedic implants to induce allergic reactions due to metal sensitisation (Cousen 2012, Zeng et al. 2013), but the evidence for these non-specified allergic reactions is rare. Therefore, this report concentrates on specifically occurring local and systemic adverse events after the implantation of MoM hip arthroplasty. Nevertheless, it would be useful to develop guidelines on the management of patients receiving MoM arthroplasties with suspected metal allergy (Cousen 2012).

4.3.3.1. Local adverse effects

Local tissue responses to metal particles around the operated joint are possible and have been described grossly as “metallosis” in the past. Willert et al. (2005) introduced the concept of “aseptic lymphocytic vasculitis associated lesion” (ALVAL) based on a lymphocyte dominated immunological response within the periprosthetic tissues from metal on metal hip articulations obtained at time of revision. Subsequently, Pandit et al. (2008) described the occurrence of “pseudotumours”, which are cystic/solid masses developing in relation to non well-functioning metal prostheses (i.e. patients with hip complaints, clinical and/or radiographic abnormality). In a recent article, Natu et al. (2012) developed a generic all encompassing term “adverse reactions to metal debris” (ARMD), which summarises the histopathology seen in association with MoM hip arthroplasties including ALVAL, lymphoid neogenesis, granulomatous inflammation and metallosis.

The clinical spectrum of ARMD is large and ranges from small asymptomatic cysts to large cystic or solid soft tissue masses (pseudotumours) as well as large osteolyses with bone destruction around the prosthesis (fig.2). Diagnosis of tissue destruction is possible through radiographs and/or ultrasound examination, computed tomography (CT) and MRI with metal artifact reduction sequence (MARS-MRI).

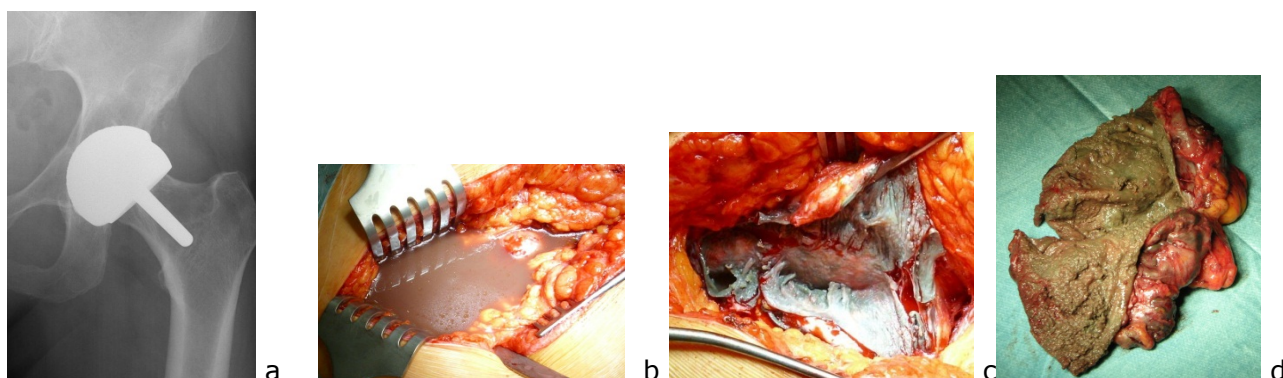


Fig. 2: Osteolysis (superiorly to the acetabular component, a) and different formations of cystic/solid soft tissue masses in ARMD (b, c, d) (Source: K. P. Günther)

The prevalence of ARMD around MoM-joints is difficult to determine, as the number of systematic studies with appropriate design is still very small. Therefore, the published

incidence of pseudotumours in large-head MoM THA and HRA ranges from 0 - 61% in different cohorts (Bisschop et al. 2013, Kwon et al. 2010, Matthies et al. 2012, Williams et al. 2011, Daniel et al. 2012). The large spectrum of pathological findings is probably due to different type/size of implants, different imaging tools and a selection of symptomatic patients (non well-functioning cases) versus cross-sectional screening in asymptomatic patients. Wiley et al. (2013) recently performed a meta-analysis of 14 published reports on the incidence of pseudotumours and ALVAL reactions in MoM arthroplasties (total of 13,898 MoM implants). Mainly large-head and resurfacing MoM implants were included. The incidence of pseudotumour/ALVAL ranged from 0% to 6.5% of hips with a mean follow-up ranging from 1.7 to 12.3 years across the studies. They calculated a pooled estimated incidence for pseudotumour/ALVAL of 0.6% (95% CI: 0.3% to 1.2%).

In small-head MoM-THA, the incidence of ARMD seems to be very low, as only a few case reports exist (Baur et al. 2005, Gruber et al. 2007), although several hundred thousand prostheses have been implanted in the last three decades.

4.3.3.2. Systemic adverse effects

There are some specific concerns related to the possible systemic exposure to cobalt and/or chromium after MoM hip arthroplasty, such as systemic organ toxicity, carcinogenicity and teratogenicity.

Systemic toxicity:

The published evidence on metal-related systemic toxicity in patients with hip arthroplasty and especially MoM implants is rather limited. In some case studies, the potential clinical picture of "arthroprosthetic cobaltism" is highlighted (Oldenburg et al. 2009, Tower 2010, Machado et al. 2012, Sotos and Tower 2013, Zywił et al. 2013). Tower (2010) reported two patients with Articular Surface Replacement (ASR) implants. Massively elevated anteversion in one case and a significant mismatch of head- and shell-diameter in the second case due to surgical faults resulted in severe abrasive wear and cobalt serum ion elevation (up to 122 µg/L). The patients reported anxiety, headache, irritability, fatigue, tinnitus, hearing loss, cognitive decline, and depression. Most symptoms improved after revision surgery. There is impressive evidence from a case report of a broken ceramic head with revision to MoP THA (Oldenburg et al. 2009). High levels of cobalt due to massive deterioration of the metal femoral head caused by overlooked particles of the broken ceramic head led to hypothyroidism, peripheral neuropathy, and cardiomyopathy. Most of the symptoms disappeared after a second revision and replacement of the scraped metal head. Recently, another patient died due to cobalt-induced cardiomyopathy six months following revision of a fractured CoC total hip replacement to a MoP bearing. Massive weight loss of the metal head as a result of severe abrasive wear by ceramic particles embedded in the revision polyethylene liner led to a peak whole blood cobalt level of 6521 µg/L (Zywił et al. 2013).

Leikin et al. (2013) performed an observational study of 39 hip arthroplasty patients (26 of them having MoM THA), who were investigated at two outpatient medical toxicology clinics. Twelve patients were symptom-free, nine complained of fatigue and two other patients had been previously diagnosed with fibromyalgia. A major complaint was tinnitus/hearing loss in 12 patients, but no difference between the incidence of this symptom in MoM and non-MoM implant patients could be observed. Of three patients with provisional diagnosis of demyelinating neuropathy, one patient experienced marked improvement after revision surgery. Overall, 20 patients underwent revision surgery of their THA and surgery was associated in a decrease of metal ion levels. The patients' subjective complaints, however, did not correlate with Co and Cr ion levels.

Two recent investigations systematically looked into potential systemic sequelae of MoM hip arthroplasty (Chen et al. 2013, Prentice et al. 2013): Chen et al. (2013) studied 32 consecutive patients with a large-head MoM THA and compared their results to a matched

cohort of 32 patients with MoP THA with a mean follow-up of two years postoperatively. Serum metal ion levels, liver and kidney function and host immunologic immune responses were evaluated throughout the observation period. Mean Co and Cr levels in the LH-MoM implant group were 4.33- and 1.95-fold higher than those in the control group. Clinical scores as well as liver and kidney function parameters did not show any difference between the groups. CD3+, CD4+ and CD8+ cell levels in the LH-MoM implant group were significantly decreased, the INF- γ level was increased. Although this study revealed that subtle immunological changes can occur after MoM implantation, it is doubtful if these abnormalities are able to compromise host defence mechanisms which may play a role in foreign body reaction to metal products. Prentice et al. (2013) performed a detailed cross-sectional health screening in 35 asymptomatic patients with MoM HRA eight years after implantation and compared the results to a matched cohort of 35 asymptomatic patients after conventional THA. They found an increase of body bone mineral density by 5% and a decrease of bone turnover by 14% in the MoM group. The cardiac ejection fraction was 7% lower (mean absolute difference 25%, $P = 0.04$) and left ventricular end-diastolic diameter was 6% larger (mean difference 2.7 mm, $P = 0.007$) in the resurfacing group. There was no evidence of difference in neuropsychological, renal tubular, hepatic or endocrine function between the two cohorts. The authors concluded that chronic exposure to metal concentrations in patients even with well-functioning MoM hiparthroplasty may have systemic effects.

In several cross-sectional surveys evaluating kidney function after MoM THA and HRA, the authors did not report any clinically relevant impairment even after long follow-up times (Grubl 2007, Yang 2011, Daniel 2010, Marker 2008). In patients with chronic kidney failure and MoM-THA, only minor elevation of cobalt and normal chromium values have been documented (Hur 2008).

Van Lingen et al. (2013) recently published a detailed clinical screening of ten asymptomatic patients with very high Co levels of 18-153 $\mu\text{g/L}$ (mean 46.8 $\mu\text{g/L}$) at a mean follow-up time of 4.2 years after implantation of LH-MoM arthroplasty. Extensive neurological and cardiological investigations as well as laboratory assessment of renal and thyroid function have been performed. The authors could not identify any signs or symptoms of neurological dysfunction, cardiomyopathy, or renal or thyroid dysfunction in the cohort.

At the moment, the long-term effects of metal ions derived from MoM implants are not known. A general systematic approach to this problem is needed.

Carcinogenicity:

Only a few studies have examined the long term risks of exposure taking into account the potential latency of metal induced effects.

a) General studies

The two largest long-term studies, predominantly of patients with MoP implants, have been a meta-analysis of 9 studies by Onega et al. (2006), which included 175,166 patients, and an analysis by Visuri et al. (2010) with 24,636 patients. There was no significant difference in the overall rate of cancer in patients with MoP implants from that in the general population after short-term follow-up but a slight increase with time post-operatively. Immediately after surgery, the incidence of cancer of the gastrointestinal tract and lung was much reduced, which might reflect less smoking in patients fit for surgery coupled with treatment with non-steroidal inflammatory drugs, which are protective for colorectal cancer. In contrast, the incidence of cancer of bladder, kidney and melanoma was not affected immediately after operation but had increased by 5-9 years (bladder 1.13) and >10 years (kidney 1.22, melanoma 1.43) in the Onega study and similarly in the Visuri study from 0-2 years (kidney 0.91, melanoma 0.88) to >20 years (kidney 1.65 melanoma 1.84). Visuri and his study group also published extended data on a large Scandinavian cohort of patients not only with total hip (THA) but also total knee arthroplasty (TKA). Two groups of 49,000 THA patients and 24,000 TKA, patients were partly adapted and combined for meta-analysis at a mean and maximum follow-up time of 6.8 and 30 years, respectively. Standardised incidence ratios (SIRs) for the observed number of cancers in the arthroplasty cohorts were compared with expected rates

based on national incidence. The overall SIRs as well as the site-specific ones were similar in THA and TKA patients. The observed number of cancers at all sites was lower in the arthroplasty cohort than in the normal population. The SIRs for lung cancer (0.69, 95% CI 0.64-0.75), laryngeal cancer (0.64, 0.44-0.92), cancers of the stomach (SIR 0.76, 0.67-0.84), colon (SIR 0.86, 0.79-0.93) and rectum (SIR 0.89, 0.80-0.98) was also reduced. Among TKA patients, the only increases in SIRs were seen in cancers of the endometrium (SIR 1.36, 1.05-1.74), prostate (SIR 1.19, 1.02-1.38) and, among both THA and TKA patients, in skin melanoma (combined SIR 1.21, 1.03-1.41).

Wagner et al. (2011) analysed data from a large cohort of patients with knee replacement from the Swedish Knee Arthroplasty Registry and compared the incidence of cancer to the overall national cancer incidence in Sweden. For all TKA patients, the overall cancer risks were elevated, ranging from 1.10 (95% confidence interval (CI): 1.03-1.18) for men with primary osteoarthritis to 1.26 (1.23-1.29) for men with rheumatoid arthritis. The greatest increases in risk were observed for the leukaemia subtypes, myelodysplastic syndromes and essential thrombocytosis. Increases in risk were also observed for breast cancer, prostate cancer and melanoma. The authors also performed an analysis of cancer latency period in order to identify potential aetiological factors. This analysis revealed that increases in myelodysplastic syndrome and possibly prostate cancer and melanoma rates appeared to be connected to the operation. This study highlights the fact that a potential release of metal products and an association with systemic adverse effects is not only limited to patients with hip arthroplasty, and especially MoM-implants, but can probably occur also in other patients with all types of metallic medical implants.

b) Studies focussing on MoM implants

Dunstan et al. (2008) have found a larger number of chromosomal aberrations (structural aberrations aneuploidy gain) in a MoM implant patient cohort when compared to individuals without metal implants. They summarised, however, that the clinical consequences of the observed chromosomal changes are unknown and emphasise the need for additional investigation.

Visuri and co-authors published several studies where patients with MoM hip arthroplasties as well as other bearings have been compared to the general population in Scandinavian countries (Visuri et al. 2006, Visuri et al. 2010, Mäkelä et al. 2012): Combined data analysis from Nordic registries (Visuri et al. 2006) showed extended life expectancy and similar overall cancer incidence for all hip arthroplasty patients when compared to the general population. The rate of stomach and colorectal cancer was significantly reduced, while the rate of prostate cancer and skin melanoma was significantly increased in the THA cohort. All-site cancer incidence of a historic "first-generation" MoM implant (McKee-Farrar prosthesis) was not different from the general population after a maximum follow-up of 28 years. The same prosthesis was analysed in a consecutive investigation (Visuri et al. 2010): standardised mortality ratios (SMR) of total and site-specific causes of death for 579 patients with McKee-Farrar THA and 1585 patients with MoP THA after a mean follow-up time of 16-17 years have been calculated. In comparison to the normal Finnish population, both cohorts showed decreased mortality for the first decade postoperatively, equal mortality over the next 10 years, and increased mortality after 20 years. The overall SMR was 0.95 for the MoM cohort and 0.90 for the MoP THA cohort. MoM patients had higher cancer mortality (SMR 1.01) than those with MoP THA (SMR 0.66) during the first 20 years postoperatively, but not thereafter. The authors conclude that both implants are safe based on total and site-specific mortality of recipients during the study period.

Although this conclusion is limited by a relatively small cohort size, it is important to note that wear rate and metal ion release in some of the historic McKee-Farrar prosthesis was substantially higher than those of modern design MoM implants due to the higher dimensional tolerances. Similar amounts of metallic debris can be expected with modern implants in unfavourable wear situations resulting in boundary lubrication. Mäkelä et al. (2012) recently calculated the relative risk of cancer (expressed as the ratio of observed to expected number

of cases from the Finnish population) in 10,728 patients with MoM-THA after a mean follow-up of four post-operative years and 18,235 patients with conventional THA in the Finnish Arthroplasty Register. In this investigation, the overall risk of cancer in patients with MoM hip implants was not significantly different from that in the Finnish population. They observed a higher than expected incidence of basal cell carcinoma in the MoM hip implant cohort, offset by a lower incidence of lung cancer. According to the authors, these effects may be due to confounding variables, as relevant influencing factors (i.e. smoking, body mass index) have not been analysed.

In two other investigations of National Joint Replacement Registry data, an analysis of large patient cohorts has been performed: Brewster et al. (2013) published a linked database of hospital discharge, cancer registration, and mortality records in Scotland, where indirectly standardised incidence ratios (SIRs) have been calculated for selected cancers in patients with primary THA (MoM THA as well as other bearings, operated in 1990-2009) and MoM HRA (2000-2009). For the analysed population of 71,990 patients and the total period of observation combined, the risks of all cancers (SIR: 1.05; 95% CI: confidence interval 1.04-1.07), prostate cancer (SIR: 1.07; 95% CI: 1.01-1.14), and multiple myeloma (SIR: 1.22; 95% CI: 1.06-1.41) were increased. For the 1317 patients with MoM HRA, there was no significant increase of SIR for all cancers (1.23; 95% CI: 0.87-1.68). A weakness of this study is again the short follow-up of patients with MoM implants and inadequate adjustment for potential confounding factors. Smith et al. (2012) directly compared the incidence of cancer in 40,576 patients with MoM hip arthroplasty and 248,995 patients with alternative bearings, linking the National Joint Registry of England and Wales to NHS hospital episode statistics. They found neither an overall increased risk of a diagnosis of cancer nor an increase in malignant melanoma or haematological, prostate, and renal tract cancers. The mean follow-up of three years in this study is short.

Teratogenicity:

Although a teratogenic potential of chromium and cobalt is well known, there are currently no documented clinical cases. Different opinions exist regarding the extent to which a transplacental transfer of metal products is possible. Ziaee et al. (2007) as well as deSouza et al. (2012) observed a trans-placental passage of metal ions in women with HRA, but the ion levels in newborns were significantly lower than the levels in their mothers' blood. Both authors could not identify any teratologic effects. One other study (Brodner et al. 2004) did not find elevated metal ion levels in newborns after small-head MoM THA in their mothers. Johnson et al. (2013) recently described their experience with a cohort 48 women who had received MoM HRA at childbearing age (40 years or younger at surgery). Eleven women reported pregnancies and eight returned the survey indicating that children were not born with birth defects and all of them appeared to be developing normally. No serum ion levels in these patients were reported. Further results of larger cohorts are still lacking. A clear limitation of all investigations to date is that no measurement of cord blood was performed in female patients with extremely high metal ion levels. Due to the potential of transplacental metal ion transfer, therefore, MoM-arthroplasty is not recommended in female patients of childbearing age.

One study has analysed potential teratogenic effects in male patients: Nikolaou et al. (2013) determined Co and Cr concentrations in both the seminal plasma and blood of 11 young male patients with MoM hip arthroplasty as well as in a control group (n=4). The cobalt level was higher in the seminal plasma of (2.89 µg/L) compared to control patients (1.12 µg/L) (P = .011). The clinical implication of this finding, however, is unclear.

Conclusion:

Currently, the database for systemic organ toxicity, carcinogenicity and teratogenicity in patients with MoM prosthesis is limited. Due to the complexity of the exposure to the metallic products (mainly cobalt and/or chromium) including particles, ions and still uncharacterised

metallo-organic compounds, it is difficult to perform a quantitative estimate of the risk on the basis of ionic blood levels, referring to the toxicological profile of single metals. Metal products released into body fluids are deposited in lymph nodes, bone marrow and internal organs. Therefore, it is extremely difficult to define the exact risk of systemic adverse effects.

4.3.4. Factors influencing the outcome: surgeon, patient and implant

Recent studies have shown that surgical positioning of MoM implants is closely associated with outcome: from biomechanical investigations and clinical studies of HRA cohorts, it is well known that edge-loading and microseparation/subluxation are main triggers for accelerated wear and metal particle release (Griffin et al. 2010, Langton et al. 2011). Therefore, it is critical to achieve a good cup position with inclination below 50° and anteversion of 10-20°. An implant position outside this "safe zone" is correlated with higher serum ion concentrations and increasing risk of pseudotumour formation (De Hahn et al. 2008, Desy et al. 2011, Langton et al. 2011, Hart et al. 2011, Hartmann et al. 2013).

Several observational studies after implantation of MoM HRA, as well as analyses from Arthroplasty Registries, have also revealed patient-related risk factors for poor outcomes: These include being female (Hart et al. 2011, Australian Registry 2011, National Joint Registry 2011, Hartmann et al. 2013, Sehatzadeh et al. 2012), and particularly being female and less than 40 years of age (Glyn-Jones et al. 2009). Ten years post-operatively the revision rate in Australian female patients (16.9%) is nearly three times higher than the revision rate in male patients (6.1%)(Australian Arthroplasty Register 2012). It is not clear why women generally seem to have a higher revision rate than men. Contributing factors could be allergic predisposition, increased range of motion (more likely leading to impingement) and different gait patterns (Glyn-Jones et al. 2009). Inferior results for female patients could also at least partially be attributed to lower femoral head sizes. It is well known that small implant diameters are associated with the poorest outcome. This is mainly due to a reduced functional arc coverage, which negatively influences the load transmission in small diameter implants (Griffin et al. 2010). The Australian Registry shows a 10-year revision rate for HRA with femoral head size ≥ 50 of under 5%, while implants with a head size ≤ 49 mm have a 12% revision rate (Australian Orthopaedic Association National Joint Replacement Registry 2012). Although the effect of femoral component head size is independent from gender, female patients tend to receive smaller implants than men. Another independent risk factor for poor outcome is patient age, as there is a higher rate of revision for patients above the age of 65 years (Australian Arthroplasty Registry 2012). This difference can only be observed in the first six months after surgery, where femoral neck fractures are a main cause of failure. Regarding the influence of physical activity on survival rates, the results are controversial, as some studies report positive associations (Desy 2011, Langton 2009) and some report negative associations (Daniel 2009, Vendittoli 2007). It is also unknown if the risk factors for inferior outcome in MoM HRA as discussed above also apply to small-head and large-head MOM arthroplasties.

Several recent studies have shown that the implant *per se* is influencing the amount of metal particle release and also clinical outcome. Small-head MoM THA Metasul® implants show better survival than implants consisting of other materials (Grubl et al. 2007, Eswaramoorthy et al. 2008, Zenz et al. 2009, Korovessis et al. 2006, Milosev et al. 2006, Park et al. 2005, Repantis et al. 2013). For resurfacing implants, the Australian Arthroplasty Registry (2012) as well as clinical studies (Langton et al. 2009, Langton et al. 2011) and a health technology assessment (Sehatzadeh et al. 2012) also report different survival rates depending on the type of implant. In the Australian registry, the seven-year implant revision rate is 5.1% for BHR®, 9.3% for DUROM®, 12.4% for Cormet® and 23.4% for ASR®. As extremely poor results for the latter implant have also been documented in clinical studies (Langton et al. 2011), this prosthesis was withdrawn from the market. Design characteristics as well as material properties may be responsible for the different performance of individual implants (Griffin et al. 2010, Langton et al. 2011). Currently, the BHR® prosthesis is still performing well in the Australian Registry with an overall survival rate of 92.9% at 11 years post-operative (Australian Arthroplasty Registry 2012).

4.3.5. Conclusions

The product survival rates and local adverse reactions after MoM hip arthroplasty depend on the type of implant as well as patient and surgeon specific factors. While the overall long-term survival rates of MoM implants are lower than the survival rates of conventional THA implants, certain subgroups (i.e. well-performing types of small-head MoM THA and well-performing HRA implants in young male patients) seem to have comparable results. In HRA, female gender, small femoral component size and edge loading due to high cup inclination/anteversion are major risk factors for poor product survival and the development of local adverse reactions. Even well-functioning MoM implants, however, release metal particles, which can induce local as well as systemic adverse reactions.

Regarding the functional outcome and health-related Quality-of-Life, there is no overall difference between MoM implants and conventional THA. Selected subgroups (young and active male patients), however, may profit from HRA.

Conclusions are preliminary regarding the benefit and the risks of MoM THA and HRA, because there are only a limited number of systematic long-term follow-up studies. The seriousness of some case reports of both local soft tissue damages and systemic toxicity would suggest that prudence is called for when implanting MoM prostheses. Registry data of carcinogenicity are reassuring because there is as yet no evidence of an overall increase in cancer associated with MoM hip arthroplasty. However, repeated analyses of sufficiently large patient cohorts and longer follow-up studies are necessary based on reports indicating elevated rates of melanoma, hematopoietic malignancy, prostate cancer in patients with all types of orthopaedic implants.

4.4. Diagnostic tools needed for clinical decision-making

In addition to the clinical investigation, the classical imaging tools like X-rays, ultrasound, MRI and CT are available for the follow-up of hip arthroplasty. As MoM implants release metal particles and ions, their levels can be determined in various liquids/media (mainly blood, serum and urine and possibly also in hair or nails), which may prove useful in the decision process regarding the implant revision.

4.4.1. Imaging studies

Imaging techniques in MoM THA as well as HRA are applied to determine structure and function of implants, periarticular tissues and/or internal organs, which may be affected by metal products. Indications for the application may be either routine follow-up examinations in asymptomatic patients or a search for potential adverse events in symptomatic patients. The most commonly used imaging techniques are radiographs, ultrasound (US), computed tomography (CT) and magnetic resonance imaging (MRI). This chapter will focus on diagnostic imaging of implants and periarticular tissues; organ-related diagnostic assessment follows the principles of involved medical specialties (e.g. cardiology, nephrology, neurology).

4.4.1.1. Radiographic imaging

The basis of every diagnostic assessment after MoM THA as well as HRA is a conventional radiograph (antero-posterior pelvic radiograph and lateral view), which is appropriate in routine follow-up investigations as well as in symptomatic patients. The goal of the radiographic investigation is to obtain information on the implant (e.g. type of the implant, bony fixation, position, potential wear) and the quality of periarticular bone (e.g. lucency, osteolysis, osteoporosis) on the femoral as well as acetabular side. Plain radiographs are useful in symptomatic patients to assess component position and detect femoral neck fracture, aseptic loosening, heterotopic ossification or bone destruction from ARMD (Fang et al., 2008). While radiographs of small-head and large-head MoM THA as well as the acetabular component of HRA can be assessed similarly to conventional THA, femoral components of HRA require different evaluation protocols. Instead of a large stem extending over the metaphysis into the femoral canal in conventional THA, there is only a small peg which reaches into the metaphysis. In addition, the metallic femoral implant overlies the junctions between bone-cement and cement-prosthesis, which impairs the assessment of interactions between bone and cement. The short peg can be used, however, to determine periprosthetic bone quality (assessment of lucencies around the peg) and positioning of the implant.

While plain radiographs are important to assess implant position and bone quality, they cannot display potential soft-tissue destruction associated with MoM implants (Toms et al. 2008, Duggan et al. 2013, Rahman et al. 2011, Chen et al. 2011).

4.4.1.2. Ultrasound (US) examination

Patients with unexplained pain and normal radiographs require further imaging of the soft tissues. Ultrasound is an accurate method of assessing soft tissue pathology and may be used effectively in the assessment of the painful hip after MoM hip arthroplasty (Siddiqui et al. 2013). Prior to CT and/or MRI, US is a simple and safe investigation technique if the examiner is appropriately trained. Several investigators (Pandit et al. 2008, Williams et al, 2011, Kwon 2011, Garbuz et al. 2013) have shown that ultrasound is capable of detecting pseudotumours associated with MoM implants. Garbuz et al. (2013) compared US with MRI for pseudotumour detection in asymptomatic MoM implant patients and found a sensitivity of 100% and specificity of 96% for US. They conclude, that US is a cost-effective screening tool to rule out pseudotumours in pain-free patients with well-functioning prostheses.

Although image quality of a deep structure such as a suspected peri-prosthetic pseudotumour or fluid collection is dependent on several factors (i.e. experience of examiner, technical equipment, size of patient and lesion), an adequate examination can be achieved with the use of the appropriate US probes and careful technique. Besides the presence of pseudotumours and fluid collections, trochanteric bursitis, heterotopic ossification and femoral neck thinning can also be diagnosed. US is also useful to guide the aspiration of hip intra-articular fluid or a peri-prosthetic cyst or bursa.

The main limitation, however, is that US must be considered as a highly investigator-dependent technique. The inter- as well as intra-observer reliability of sonographic pseudotumour diagnosis has not yet been proven in any study.

4.4.1.3. Computed tomography (CT)

CT scan is a well-established diagnostic method for detecting and quantifying peri-prosthetic osteolytic lesions, especially in the acetabulum where they may be difficult to detect on plain radiographs because of the overlying prosthetic cup. CT scans can also detect and delineate solid or cystic masses adjacent to a MoM THA or HRA, both on axial and coronal images reformatted for reduction of metal artifacts (Duggan et al. 2013). Bosker et al. (2012) could

detect pseudotumours in their patient cohort by CT investigation as well as by MRI Investigation with similar reliability.

A CT grading system for describing capsule abnormalities was recently developed and seems to show good interobserver reliability (Boomsma et al. 2013). CT is also utilised to assess acetabular cup position (i.e. anteversion) as a major influencing factor on implant wear and metal ion release. In addition to the diagnostic value of CT, it can be used for imaging guidance when performing aspirations or biopsies. CT examinations always expose the patient to additional radiation dosage. The latest technical developments, however, especially the iterative post processing techniques of various vendors, significantly reduce the patients' exposure to radiation. The latest metal artifact reduction software by various vendors is capable of improving image quality with improved visibility of the capsule, making it easier to detect pathology due to the reduction of the metal artifacts caused by the metallic components of the implants. Furthermore, CT is capable of assessing bone mineral density of the acetabulum roof with the use of special techniques (Mueller et al. 2009).

4.4.1.4. Magnetic resonance imaging (MRI)

MRI is the current gold standard for the identification and detailed description of soft tissue abnormalities. In MoM implants, however, special MRI techniques are necessary to reduce metal artifacts. Metal Artifact Reduction Sequence (MARS) MRI can produce diagnostic quality images of periprosthetic bone and soft tissues lesions following MoM hip arthroplasty (Duggan et al. 2013). Soft tissue lesions associated with MoM hip arthroplasty have characteristic features on MRI: they appear either as cystic fluid collections confined by a pseudocapsule, or solid masses which are more difficult to delineate. Magnitude, location of the lesion, communication with the hip joint and invasion or destruction of surrounding structures can be accurately assessed. According to Garbuz et al. (2013), MRI has a sensitivity of 92% and a specificity of 100% in the detection of pseudotumours. Synovial volume on MRI may also reflect the degree of adverse local tissue reaction (Nawabi et al. 2013) in the absence of pseudotumours. Although MRI also allows for evaluation of neighbouring bone, muscle and tendon, the MRI images are sometimes not specific enough to differentiate between wear-induced lesions, infections or some neoplastic pathologies. In those cases, gadolinium-enhanced MR imaging and additional tests such as cultures of aspirated fluid or histological examination of biopsy material may be necessary.

Anderson et al. (2011) have developed a reliable MRI grading system for the severity of soft tissue changes associated with MoM THA, which depends on the presence and size of periprosthetic soft tissue masses or fluid-filled cavities, muscle or bone marrow edema and tendon avulsion. According to this classification, normal post-operative appearances and infections are distinguished from "mild", "moderate" and "severe" disease.

4.4.2. Measurements of metal/metal ions in body fluids

4.4.2.1. Sample sources

For the assessment of metal ion levels in patients with a MoM hip prosthesis various matrices, such as whole blood, serum, urine and hip fluid may be used. Analyses in whole blood or serum are preferable, since the metal ion concentrations in urine samples are variable and depend on the hydration of the patient, unless corrected for creatinine content. Twenty-four hour urine concentrations are more reliable but a 24-hour urine collection is cumbersome and often incomplete. Urine samples should be collected avoiding metal contamination as well. Although there is a good correlation between blood and 24-hour urine values, blood is definitely the matrix of choice for routine use, either whole blood or serum. There is no consensus to date on which matrix (whole blood or serum) is superior and both matrices are used in routine clinical practice. Serum or plasma as a source is less complete since the

intracellular Cr ions, particularly in the red blood cells (RBC), are not included. Practically, it is very important to be consistent in using the same matrix when comparing consecutive metal ion values of the same patient or when comparing values of different patients or from different centres.

Analytical methodology

Levels of cobalt and chromium are measured using an inductive-coupled plasma mass spectrometry (ICP-MS) technique. Other measuring analytical methods like Graphite Furnace Atomic Absorption Spectrophotometry (GFAAS) can be used but ICP-MS is known to have lower detection limits and the possibility for simultaneous multi-element determination.

One of the major technical challenges of biological metal ion testing is the risk for contamination from needles, collection tubes or containers and thus rigorous protocols and controls are advocated for every step of the process.

The use of 'trace elements collection tubes' either without anticoagulants or with K₂EDTA is recommended. Transfer pipettes, and other disposables if necessary, must be pre-washed with 0.5 % (v/v) nitric acid and rinsed with distilled water.

Sample volume needed for metal ion analysis

1 millilitre (mL) of serum or plasma and 2 mL of whole blood is sufficient for analysis. A 5 mL urine fraction taken either from a urine sample or a 24-hour collection is sufficient for analysis and back-up storage.

4.4.2.2. Protocol for blood sampling

It is preferable to use a non-metal needle but a metal needle can also be used, provided the first 5 mL of blood are discarded in order to eliminate the metal ions from the needle. Therefore, blood samples should be collected using an intravenous catheter. After the catheter is introduced, the metal needle is withdrawn and the first five millilitres of blood are discarded to avoid possible metal contamination from the needle. A subsequent second five millilitres of blood are collected

Metals are rather stable in serum or whole blood and shipping at room temperature is allowed if it takes less than three days. The samples can be stored at 4°C for up to one week before shipping them. The samples can be stored frozen (- 20°C) for months.

4.4.2.3. Interpretation of metal ion levels

For a correct interpretation of metal ion levels, other possible sources of metal ions in blood or urine have to be excluded. Exposure to metal ions may be occupational (e.g. leather, dye, diamond industries) or environmental (air, water, soil pollution). The implantation of any metal device into the body will inevitably lead to release of metal ions either secondary to wear or to corrosion. Intravascular stents (Ni and Cr) and dental implants (Ti) but also dental orthodontic brackets and wires (Ni, Cr, Fe, Ag, Cu, Ti) are known to release metal ions. Potential sources of metal debris from orthopaedic implants are not restricted to the bearing surfaces of MoM articulations (including knee arthroplasties and artificial lumbar discs) but may be related to interfaces with bone, cement, modular parts, screws or to delaminating metal coatings, internal fixation devices or spinal fixation devices. Intake of Co and Cr ions through medication, vitamins, or dietary substitutes is a frequent source of elevated metal ion levels. Equally, smoking and abuse of soft- or hard-drugs may lead to elevated metal ion levels. Finally, since Co and Cr are primarily excreted by the kidneys, renal impairment and insufficiency will lead to higher levels of metal ions (Brodner et al. 2003) and may be considered as a contraindication for the implantation of MoM hip arthroplasties.

It is important to specifically question patients regarding possible exposure, implantation of metal components and the intake of metal ions and to check renal function to avoid misinterpreting elevated ion levels.

As whole blood and serum levels cannot be used interchangeably, Smolders et al. (2011) have provided a formula for conversion from serum to blood of $0.34 + [0.88 \cdot \text{Co serum}]$ for cobalt and $0.14 + [0.58 \cdot \text{Cr serum}]$ for chromium, with an acceptable prediction error below $\pm 1.0 \mu\text{g/L}$. They do not recommend the use of whole blood over serum measurements or vice versa.

4.4.3. Possibility for analysis of synovial fluid and periprosthetic tissue

The hip joint is the first compartment where metal particles are released. After MoM implantation it is therefore possible to identify them in the joint fluid as well as in periprosthetic tissue (Beraudi et al. 2013, De Pasquale et al. 2013, Langton et al. 2010, Langton et al. 2012, Nadu et al. 2012). It is, however, more difficult to retrieve synovial fluid samples or even tissue biopsies than to draw venous blood.

De Pasquale et al. (2013) performed an investigation to assess the correlation between particles in the synovial fluid and circulating Co/Cr ions in whole blood as well as serum samples of 40 patients after a mean post-operative follow-up of 4.4 years. In nearly half of the cohort, no metal particles could be identified in the synovial fluid and the whole blood Co level in these patients was $0.05\text{--}4.42 \mu\text{g/L}$. In the remaining patients, a strong positive correlation between synovial fluid Co/Cr particles and the blood metal ions could be determined. The highest correlation existed for metal particles and cobalt levels. Although the authors conclude that systemic Co and Cr levels represent the local intraarticular particle release and can therefore be used for the monitoring of wear processes, further investigations are necessary to apply these data to clinical practice.

Regarding metal deposition in periprosthetic tissue (i.e. joint capsule), characteristic histologic responses have been described (Willert et al. 2005, Pandit et al. 2008, Langton et al. 2010, Langton et al. 2012, Nadu et al. 2012). According to Natsu et al. (2012), the spectrum of changes seen in ARMD is distinctive. There is a "conglomerate of surface necrosis, with macrophagic response containing fine metallic debris, sometimes forming granulomas, along with an evolving ALVAL /perivascular lymphocytic infiltrate with or without germinal centres". As the amount of surface necrosis is variable, it can be difficult to distinguish the tissue response in ARMD from other chronic inflammatory arthropathies. Metal particle load in peri-articular tissue can be graded (Langton et al. 2010) to allow for a correlation with the rate of volumetric wear. The current value of histologic analysis, however, must be seen in the post-hoc analysis of retrieved tissue samples after revision surgery (to confirm the diagnosis of ARMD). Currently, it is not possible to use histological grading to correlate the pathologic tissue response and clinical problem, especially in early stages of local adverse reactions, to make a decision to revise a joint.

4.4.4. Conclusions

Various diagnostic tools are available for routine screening as well as for the investigation of symptomatic patients after MoM hip arthroplasty. In addition to clinical examination plain X-rays are the primary measure to obtain information on the implant as well as the quality of periarticular bone. Ultrasound and MARS-MRI can be helpful to detect local adverse soft tissue reactions (i.e. fluid accumulation and pseudotumours), while CT investigation is mainly used to quantify bony destruction.

Assessment of metal ion levels can be performed in whole blood, serum, urine and joint fluid. Currently, for routine purpose the analysis of Co-concentration in whole blood or serum is preferable. To assure validity and reproducibility, the adherence to standardised protocols for sample collection and analysis is mandatory. Measurements of metal particles and/or metal

ions in synovial fluid and prosthetic tissue could be helpful in analysing a potential correlation between local metal particle deposition and local or systemic adverse effects. However, appropriate technologies to measure deposited (metallic) particles in tissues are still a subject of research.

4.5. Metal toxicology

4.5.1. General issues

Several different metal alloys are used in MoM implants. The bearing surface itself is mostly made from CoCrMo-alloys. They may in addition contain small amounts of nickel (Ni), iron (Fe), manganese (Mn), silicon (Si). The alloys are manufactured either wrought, cast, annealed and sometimes heat-treated. They can be additionally coated with chromium-nitride (CrN), chromium-carbon-nitride (CrCN), titanium-nitride (TiN) or titanium-niobium-nitride (TiNbN). For allergy patients, coated Ti-alloys may be used as bearing articulations. The metal shell of modular cups and the stem are typically made of Ti-alloys in different compositions. In addition to Ti, these alloys may contain Al, V, Mo, Si, and Fe in varying percentages. These components are sometimes coated with hydroxyapatite. Monobloc cups are always made from CoCr-alloys. The outer surface is sometimes coated with a plasma sprayed titanium coating.

In the compound of an alloy, the specific properties of the pure elements, such as toxicity and allergenicity of cobalt, chromium and vanadium become almost insignificant; this fact is responsible for the biocompatibility of the alloys. Metallic implant materials should be as corrosion resistant as possible, but the conditions of use may render them susceptible to degradation by various pathways.

The MoM arthroplasty leads to a release of metal containing products, including a large set of forms such as metallic particles, alloys, salts, and ions which can in addition form metallo-organic compounds. These metal containing products have been found in body fluids, lymph nodes and organs.

For all metals and metal salts, bioavailability is highly dependent on the route of exposure, the solubility of the metal or metal salt in water/tissues, and particle size. The deposition of metals in the body may result in local and systemic adverse health effects. Unfortunately, analytical techniques cannot differentiate easily between these different forms of metallic compounds hampering linkage to the effects to specific compounds.

Adverse reactions to metal debris and metal ions (ARMD) are now well recognised. These reactions are manifested either as inflammatory fluid collections or as cystic or solid non-infectious soft-tissue masses around the hip or as osteolytic lesions.

The reactions can be subdivided into 2 categories. One category, called "metal reactivity," is an innate immunity response manifested as a nonspecific foreign-body reaction. This is a normal immunologic response to a large amount of metal debris, is the most common local adverse reaction, and invariably occurs with increased wear. With well-positioned, well-functioning HRAs, they are rare, but do occur more frequently with large diameter MoM THAs as a result of enhanced taper/ trunnion wear.

A second category, called "metal allergy," is an adaptive immune response manifested as delayed type IV hypersensitivity, an abnormal response to a small amount of metal debris that occurs in people with an allergic predisposition.

Information on metal toxicity is available in Toxicology textbooks, since it is a well-established field, but it is of limited use in the present context because the degradation products are not adequately characterised. This is an important area for further research.

4.5.2. Conclusion

Case reports and first results of observational studies (see chapter 4.3.3.2. "systemic toxicity") indicate that toxic reactions are possible after exposure to high metal ion levels in malfunctioning MoM implants.

The application of toxicology data from either animal studies or occupational studies for evaluation of adverse effects of metals in patients with MoM hip arthroplasties is currently limited, since the degradation products are not adequately characterised. This is an important area for further research.

4.6. Clinical strategies for the management of patients with implanted MoM

Since safety concerns after the implantation of MoM implants have been raised, several health authorities and scientific societies in different countries have published recommendations for patient management (Afssaps, BHS, Dutch Orthopaedic Association, Lombardi et al. 2012, MHRA, Health Products and Food Branch Inspectorate HC). Relevant recent statements are listed in the Annex.

Other relevant comments as published by individual authors and research groups as well as recently established recommendations from a European multidisciplinary expert group, which was endorsed by the European Federation of National Associations of Orthopaedics and Traumatology (EFORT), shall be summarised in the next chapters.

4.6.1. Recent opinions and comments

Predictive value of metal ion screening

Two reviews on blood and serum ion concentrations of Cr and Co following various MoM hip arthroplasties have recently been published. Jantzen et al. (2013) included 43 studies and 16 different MoM implants. They calculated average ion concentrations and range from the reported mean or median ion concentrations for the different types of bearings. The average Cr concentration ranged between 0.5 and 2.5 µg/L in blood and between 0.8 and 5.1 µg/L in serum. For Co, the range was 0.7–3.4 µg/L in blood and 0.3–7.5 µg/L in serum. Hartmann et al. (2013) analyzed 104 studies with a total of 9,957 patients where measurement of metal ions in body fluids had been identified. After small-head MoM arthroplasty median Co-concentrations varied between 0.65 and 1.5 µg/L at six months and between 0.7 and 1.7 µg/L two years postoperatively. Median Co-concentrations after large-head MoM arthroplasty varied between 0.7 and 3.26 µg/L six months and between 3.77 and 5.38 µg/L two years postoperatively. After resurfacing, median serum Co-concentrations varied between 1.12 and 3.7 µg/L six months and between 0.54 and 4.28 µg/L two years postoperatively. While Jantzen et al. (2013) were unable to detect any clear difference in ion concentrations between different types of implants (MoM THA and resurfacing), the latter results - as well as reported maximum values in the study of Hartmann et al. (2013) demonstrate that Co-levels were consistently higher at all postoperative assessments in patients who received large-head and resurfacing MoM arthroplasty compared to patients who received small-head MoM implants. Both studies failed, however, to detect upper acceptable limits for Cr and Co in blood.

Several authors have tried to define cut-off levels for well-functioning versus poor-functioning prostheses (Langton et al. 2010, Langton et al. 2011, Kwon 2010 Matthies 2012, Kwon 2011, Hart 2011, Van Der Straeten 2012). In fig. 3, a selection of cobalt cut-off-levels from various studies analysing cohorts with "good" and "bad" functioning MoM implants is outlined. Due to the large range of levels in each of the two groups reported in all investigations, a significantly

large overlap can be recognised, although the average values for 'good-functioning' implant are included in a limited range (1.5-3.5 µg/L).

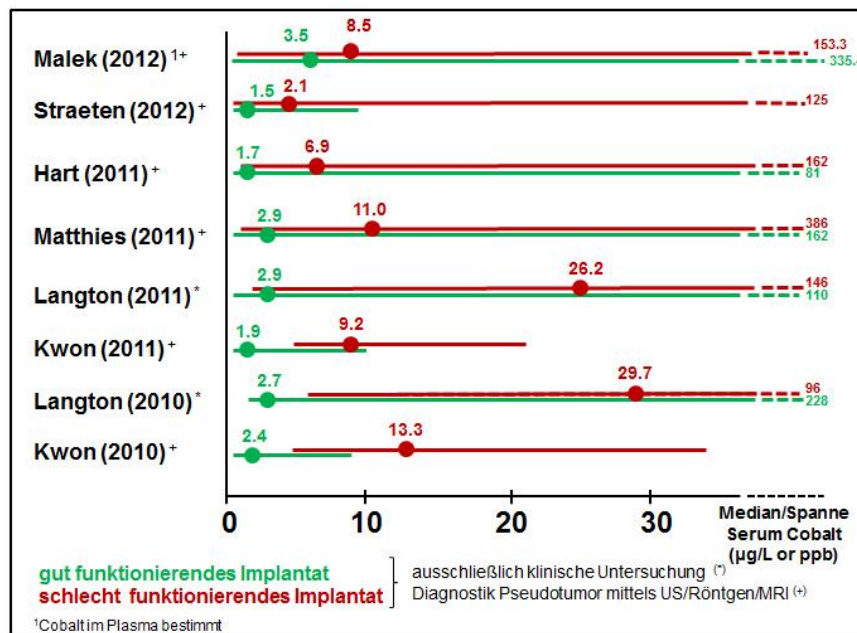


Fig. 3 Range of metal ion levels and thresholds for good (green lines) and bad (red lines) functioning MoM implants (Source: Günther et al. 2013)

Based on available data, the British Medicines and Healthcare Products Regulatory Agency (MHRA) has published Medical Device Alerts in 2010 (updated in 2012), stating that a blood metal ion level >7 ppb (=µg/L) (equal to 119 nmol/L cobalt or 134.5 nmol/L chromium) indicates potential for soft tissue reaction in MoM hip arthroplasties (<http://www.mhra.gov.uk>).

Recently, a study was conducted at a large HRA referral centre in Ghent, Belgium (Van der Straeten et al. 2013). According to the authors, the upper acceptable levels of cobalt were at 4 µg/L for unilateral and 5 µg/L for bilateral HRA. Levels above these limits had a very high probability of predicting poor function or malpositioning of the implants (specificity of 95%). These proposed levels are lower than the MHRA-levels of 7 µg/L, but they are based on strict criteria for the definition of a well-functioning HRA such as absence of clinical and radiographic findings and correct implant positioning. The high specificity and odds ratios of the proposed limits in predicting problematic HRA are concurrent with a report published by Sidiginamale et al. (2013), where outer values of metal ions with poorly functioning implants were associated with high wear (they established the upper safe levels of Co in whole blood as 4.5 µg/L with 95% specificity). Levels higher than 10 µg/L had a 100% specificity of predicting clinical problems. Hart et al. (2012) recommend a serum cobalt threshold level of 4.97 µg/L based on ROC-curve analyses. However, no explicit advice is given on how to treat patients above this value. Smolders et al. (2013) recently pointed out that metal ion trends may be more predictive for malfunctioning MoM implants than single measurements. Although their patient cohort is relatively small, the observation of larger metal ion increases over time in sub-optimal functioning HRA is interesting.

It is well known that exposure to very high levels of Co (>10 µg/L) significantly increases the risk of local and systemic adverse reactions. Considering this, Langton et al. (2013) recommend revision surgery even in the absence of symptoms for patients with grossly elevated metal ion concentrations.

Paustenbach, et al. (2014) looked into the link between Co-blood levels and systemic effects. They concluded that based on currently available data, only under very unusual circumstances

important systemic adverse effects might occur in implant patients with blood cobalt concentrations less than 300 µg/L.

Other studies are in doubt about the predictive value of metal ion determination. Van der Weegen et al. (2013) recently correlated metal ion levels with MARS MRI investigations in MoM implant patients as well as in a control group. They found normal metal ion levels in 80% of the MARS-MRI screened patients. Griffin et al. (2012) investigated 89 MoM implants with preoperative cobalt and chromium ion levels. Using 7 µg/L as a threshold, cobalt and chromium ion levels had poor sensitivity and specificity (Co, 65% and 56%; Cr, 29% and 75%). Positive predictive values for cobalt and chromium were only 48% and 26% respectively. The authors concluded that ion levels are unreliable predictors of periarticular soft tissue damage and should not be used in isolation as surgical intervention triggers. Macnair et al. (2013) also used a threshold of 7 µg/L and could show that the cobalt as well as the chromium levels in a significant proportion of their patients with MRI-documented ARMD was below this cut-off. Another recent study (Malek et al. 2013) compared cobalt and chromium investigations with MARS-MRI as the reference standard for the diagnosis of ARMD and reported a 57% sensitivity and 65% specificity of cobalt or chromium serum ion analysis with a cut-off of > 7 µg/L. A lowered threshold of > 3.5 µg/L for cobalt and chromium ion levels improved the sensitivity to 86%, but at the expense of specificity (27%). The authors, therefore, do not recommend metal ion analysis as a sole screening test in the surveillance of symptomatic MoM implant patients. In a meta-analysis of publications investigating metal ion levels after MoM THR. Hartmann et al. (2013) concluded that substantial heterogeneity in study designs, techniques and medium of metal ion assessment significantly impair the ability to draw firm conclusions about threshold levels as an indication for surgical revision.

Predictive value of imaging studies

There is clinical consensus that plain radiographs are mandatory for routine follow-up investigations after MoM hip arthroplasty as well as for the diagnostic work-up of symptomatic patients. However, radiographs underestimate the prevalence of pseudotumours in MoM patients. To assess the presence as well as the size of soft tissue lesions (pseudotumours or fluid-filled cavities, tendon avulsions), additional US or MARS-MRI investigations are necessary. Three-dimensional estimation of periprosthetic bone cysts necessitates appropriate CT controls with metal artifact reduction.

Several investigations addressed the question of whether clinical symptoms in MoM hip arthroplasty correlate with MRI findings: Chang et al. (2012) found an association between patient pain and the presence of bone marrow edema as well as abductor tendon tears, but no association between pain and the presence or size of pseudotumours. Hart et al. (2012) report similar pseudotumour frequency in MRI screening of asymptomatic patients with well-functioning MoM hip arthroplasties and patients with a painful MoM hip. Other studies also confirm that in asymptomatic patients adverse tissue reactions can be detected with MRI-screening (Thomas 2013). It seems that MARS-MRI is not only a helpful tool to investigate painful MoM hips, but it is also capable of detecting asymptomatic soft tissue lesions in patients with clinically well-functioning implants. The presence of intra-articular fluid, synovitis or small pseudotumours, however, may not necessarily indicate the need for revision arthroplasty, as pathological findings on imaging studies do not always show a good correlation with clinical symptoms. Most authors recommend, therefore, that the need for revision procedures should be based on a combination of diagnostic tools. Van der Weegen et al. (2013) present a clinical guideline for pseudotumour treatment, which is mainly based on MRI severity grading, but also includes the interpretation of metal ion levels and clinical symptoms.

In conclusion, MRI and/or CT are, in addition to conventional radiographs, useful investigations for identifying the cause of pain in a symptomatic hip and supporting surgical planning. However, further correlation of clinical and imaging data is necessary to determine the natural history of periprosthetic soft-tissue lesions to guide clinical practice.

4.6.2. European multidisciplinary consensus statement on the use and monitoring of metal-on-metal bearings for THA and HRA

A multidisciplinary European panel, which was endorsed by the European Federation of National Associations of Orthopaedics and Traumatology (EFORT) developed the following recommendations (Günther et al. 2013, Hannemann et al. 2013):

Safety assessment of patients after implantation of MoM bearings

Due to the risks of MoM bearings, systematic follow-up is recommended for all patients and all implants. For small-head MoM THA, a systematic follow-up comparable to conventional THA is sufficient. A closer follow-up is recommended, however, for large-head MoM THA (annual follow-up for the life of the joint) as well as HRA. In the latter, annual follow-up for the first five years is recommended according to local protocols for patients with conventional THA. If metal ion levels are normal at year one and two postoperatively, the frequency of further annual follow-up investigations may be changed to local protocols for conventional THA. In patients with risk factors such as small size HRA (<50mm femoral component), female gender, and low coverage arc, annual follow-up for the life of the joint is recommended.

All patients should undergo radiographic examination during follow-up. In case of clinical / radiographic abnormality, additional imaging (ultrasound, CT-scan, and/or MARS-MRI) is recommended. Ordinary MRI without MARS-technique is ineffective. In case of Co-values above a certain threshold (within the range of 2 to 7 µg/L;), additional imaging (e.g. ultrasound, CT-scan, and/or MARS-MRI) is recommended.

Monitoring of metal ions should be performed at the time of regular follow-up in asymptomatic patients. In all symptomatic patients, additional monitoring is recommended between regular follow-up investigations. Metal ion determination of body fluids can be performed in blood, serum and urine (at present measurement of whole blood is most practicable). Cobalt should be monitored as reference substance. Ion measurement must be performed under the rules of internal/external quality control (GF-AAS and ICP-MS are considered as valid). The preferred reporting units should be micrograms/liter (=ppb). The threshold value for clinical concern is expected to be within the range of 2 to 7 µg/L (exact levels have still to be determined within this range). In increased values above the threshold, additional imaging even in asymptomatic patients is recommended. Recommendations are based on local effects; critical values for systemic effects have not yet been established for patients after MoM implantation.

Indications for revision of MoM implants for safety reasons

The appropriate management for local ARMD is based on whether or not a patient has symptoms. In asymptomatic patient, small fluid collection indicative of ARMD needs close monitoring (repeated imaging is recommended). In symptomatic patients and /or patients with progressive osteolysis, large or expanding pseudotumour, and/or progressive neck thinning, and/or Cobalt-ions above threshold level, revision may be considered.

If the metal ions levels are above threshold level at first detection, but the patient is asymptomatic, the levels should be confirmed through repeated measurement in asymptomatic patients. Above a threshold of 2 to 7 µg/L (exact level still to be determined) additional imaging and closer follow-up is recommended. In case of pathological results of additional imaging and/or further significant increase of Cobalt-level, revision surgery should be discussed with the patient, as significant metal accumulation with local ARMD is to be expected (especially in Cobalt-values >20 µg/L). In case of excessive elevation (Cobalt approximately 20 µg/L or above), because of potential osteolysis, tissue necrosis, and long-term health effects, revision surgery should also be discussed with the patient. The individual risk-benefit-ratio should always be considered before intervention.

Routine monitoring of metal ions after removal of MoM bearings is not recommended.

Appropriate communication/distribution of recommendations to patients

Before intended surgery with MoM bearing implants, every patient must be informed comprehensively in written and oral form about the benefits, risks, uncertainties, and recommended monitoring concerning MoM bearings. There should be a dialogue between the patient and the surgeon. Patients with already implanted large-head MoM THA and HRA should be informed that a higher frequency of monitoring is recommended compared to conventional MoM bearings. Risks and benefits should be expressed by patient-relevant outcomes such as morbidity, health-related Quality-of-Life, and risk of adverse effects. Absolute risk estimations are preferable to relative risk estimations. It should be highlighted that a complete (100%) prediction of positive or adverse outcomes is not possible. Uncertainties concerning both, risks and benefits, should be made explicit.

The information should allow patients to make informed decisions concerning the implantation of MoM bearings as well as to provide indication for revision in problem cases involving implanted MoM. Different stakeholders including, but not necessarily limited to patient organisations, orthopedic surgeons, toxicologists, and epidemiologists should be involved in the development of the patient information. Any potential conflicts of interest of persons involved in the development of the patient information should be declared. There should be free and unrestricted access to this information and it may be disseminated in different formats, through different media, and/or through different organisations, but the information communicated through these means should be identical in content.

Appropriate communication/distribution of recommendations to surgeons and other medical disciplines

Information to surgeons should clearly and comprehensively cover the benefits, risks, uncertainties, and recommended monitoring concerning MoM bearings including product-related as well as implantation-related aspects. Communications should include the advice to assess and consider the patient's individual benefit-to-risk-ratio prior to surgery and include the recommendations as described above concerning safety assessment of patients after implantation of MoM bearings as well as indication for revision surgery. The information should be based on a systematic and comprehensive literature review and should highlight the level of evidence for any recommendation (i.e. expert opinion, single RCT, single non-RCT, meta-analysis of randomised/non-randomised studies). It should also include a declaration of potential conflicts of interest of persons involved in the development of the information. Communications should be disseminated in different formats, through different media, and/or organisations, but should be identical in content. They should also be provided to other medical disciplines (e.g. neurologists, cardiologists, oncologists, toxicologists), as patients with MoM implants may seek their advice.

4.6.3. Results of MoM implant revision surgery

The decision about appropriate indications for revision surgery of non well-functioning MoM implants must also take into account the results of these procedures. There is, however, only a small number of studies with appropriate design and follow-up available at the moment.

Most authors agree that the clinical results after revision of MoM implants are worse than the outcome after revision of other THA implants. The complication rates vary extensively but 2-3 years after revision, the complication rate for the studied cohorts is in the range of 8-38% for infections, loosening, recurrence of pseudotumour and dislocation (Grammatopolous et al. 2009, Steiger et al. 2010, Liddle 2013, De Smet et al. 2011, Munro et al. 2013, Wyles et al. 2013). It is difficult to compare those studies, however, as they describe different indications to revise and non-standardised surgical revision procedures. In addition, they report relatively small numbers and several types and brands of primary MoM prosthesis.

Therefore, no general consensus exists in the current literature regarding indications or the technical procedures for revision surgery. Certain trends, however, can be observed in

revisions of both stemmed and resurfacing MoM hips. With respect to the surgical technique, the general professional opinion reflects a uniform surgical approach and revision strategy including resection of all accessible reactive and necrotic tissue without endangering vital structures.

- If significant ARMD are observed, revision with a non MoM-articulation (if possible, CoP, CoC or MoP) is generally considered.).
- Cementless acetabular cups with a modular insert and small-head articulations may allow isolated exchange of ball and insert.
- Monoblock metal sockets, however, need removal and insertion of a new acetabular component.
- In the past, non well-functioning femoral components in HRA often had to be revised to a stemmed large-head THR with retention of the acetabular metal cup. While Ball et al. (2007) anticipated favourable result with this approach, more recent publications have demonstrated unfavourable clinical outcome of large-head THA (see chapter 4.3.1.2). Therefore this strategy is no longer recommended and full revision including removal of the acetabular metal shell in non-well-functioning HRA is now advised.
- With the recently increased awareness of potential trunnion problems, it is difficult to determine the adequate procedure in cases with stable fixation of the femoral component and trunnion wear. If substantial macroscopic damage can be observed, however, a complete revision of even a well fixed stem must be performed. Subtle damage may be compensated by the application of a new metal ball. If ceramic heads are to be used in combination with an already implanted stem, appropriate sleeve adapters are mandatory.

No consensus strategy exists regarding the appropriate timing of revision surgery in ARMD cases. Due to the higher complication rate in the presence of large pseudotumours and severe tissue destruction, revision should always be recommended once progression is observed. Future research, however, should determine risk factors for disease progression and adequate revision strategies.

4.6.4. Conclusions

Currently, no consensus exists on how patients with implanted MoM hip arthroplasties are to be managed. It is generally agreed that *asymptomatic* patients need regular follow-up (time intervals and screening investigations depending on the implant category and the presence of pathologic findings). In *symptomatic* patients, extended investigational protocols must be applied and include the analysis of metal ion blood levels (Co is recommended) and appropriate imaging techniques (i.e. US, CT and/or MARS-MRI and plain radiographs) to determine the presence of local adverse reactions and the potential of systemic adverse reactions.

Various detailed examination protocols and treatment proposals including consensus based recommendations of an European multidisciplinary expert panel are available. They differ with respect to the role of metal ion determination, imaging strategy and indication to surgical revision. However, it is generally accepted that low ion concentrations (Co <2µg/L) are rarely associated with significant local tissue damage and that significantly elevated ion concentrations (Co > 7µg/L) may indicate a problem with the articulation. Precise determination of threshold values for good versus poor implant function, including their relevance for decision-making regarding revision surgery, necessitates further investigations. Preferably, a clear association between imaging findings and systemic metal ion levels should be found. Although, local risks can vary from systemic risks, hampering such association.

4.7. Conclusions of MoM implants

4.7.1. Risk factors for MoM implants

Main risk factors for increased wear and release of metal products with subsequent development of local adverse reactions as well as potential systemic problems in all MoM implants are:

- surgeon specific: inadequate positioning of components (i.e. elevated inclination and anteversion of the acetabular component leading to edge loading)
- patient specific: female gender and small femoral head diameter (resulting in low functional arc with consecutive overload) and susceptible individuals (i.e. patients with known allergic reactions to metal)
- implant specific: unfavourable tribology characteristics (i.e. low carbon content) and design features (i.e. low functional arc) of individual implant types; large-head THA with trunnion wear due to increased friction moments.

4.7.2. Benefit factors for MoM implants

- There are no polyethylene particles in pure MoM bearings that may cause inflammation and subsequent osteolysis.
- MoM bearings produce less volumetric wear compared to conventional polyethylene.
- There is a reduced risk of fracture in MoM bearings compared to ceramics.
- MoM is currently the only material available for HRA.
- Large-head MoM THA (head diameter of 36 mm and larger) as well as HRA have a reduced risk of dislocation compared to small-head THA (< 36 mm head size). In large-head THA, range of motion increases with the head size (only up to 40 mm).
- MoM HRA allows more preservation of bone stock on the femoral side when compared to conventional THA.
- MoM HRA may be associated with superior short- to mid-term clinical outcomes (i.e. hip function, health-related Quality-of-Life) in comparison to conventional stemmed THA in well selected subgroups of young and active male patients.

4.7.3. Follow-up of MoM implants and induced adverse effects

MoM implants release metal particles which can induce adverse effects locally (periarticular bone and soft tissue damage) as well as systemically (toxicity, carcinogenicity, teratogenicity). The current database on the incidence of these potential problems in patients with MoM hip arthroplasty is incomplete and all risks can basically also apply to patients with conventional THA. Therefore, providing specific and evidence-based guidelines on the follow-up of MoM implant patients is currently not possible. General recommendations, however, can be given which are based on recent statements of European national institutions as well as on the opinion of a multidisciplinary consensus approach:

Due to the risks of MoM bearings, systematic follow-up is recommended for all patients and all implants. For small-head MoM THA, a systematic follow-up comparable to conventional THA is sufficient. A closer follow-up is recommended for large-head MoM THA (annual follow-up for the life of the joint) as well as HRA. In the latter, annual follow-up for at least the first five years is recommended, and then it may be changed to local protocols for patients with conventional THA (if metal ion levels are not significantly elevated). In HRA-patients with

special risk factors (i.e. small component size, female gender, low coverage arc), annual follow-up for the life of the joint is recommended. All patients should undergo clinical as well as radiographic examination during follow-up. Metal ion determination is currently recommended for large-head MoM THA on a routine basis and for HRA patients at least in the first postoperative years (thereafter it may depend on their clinical performance). In the case of clinical and/or radiographic abnormality or significantly elevated metal ion levels, additional imaging (ultrasound, CT-scan, and/or MARS-MRI) is recommended. A metal ion concentration within the range of 2 to 7 µg/L cobalt-concentration may currently serve as the threshold value for the necessity of further investigations. Metal ion determination for screening purposes should be performed in whole blood. Cobalt can serve as the reference substance.

It must be outlined that these recommendations are based on potential local adverse effects of MoM arthroplasties, as critical values for systemic effects have not yet been established.

Concerning follow-up, it is also noted that:

- Manufacturers should organise a post-market follow-up of their materials on the market;
- Patients need more clarification on the reimbursement of diagnostic procedures following MoM arthroplasty. In various European countries there are different health system regulations or even a lack of generally accepted rules for the payment of proposed follow-up investigations in patients with MoM implants.

4.7.4. Gaps in knowledge

The main gaps in knowledge where further research is necessary to solve relevant questions are the following:

1. Clinical relevance and significance of metal ion determination in body fluids
 - comparative value of blood and urine as screening tools;
 - effects of long-term exposure to metal ion blood concentrations between 2 and 7 µg/L;
 - reproducibility of metal ion measurements among different labs;
 - levels of metal ions after the implantation of any other kind of artificial implant (i.e. knee arthroplasty, spine implants and osteosynthesis devices).
2. Incidence and clinical relevance of local and systemic adverse effects:
 - frequency of ARMD in different categories of MoM implants;
 - frequency of potential organ toxicity, carcinogenicity and teratogenicity after implantation of MoM arthroplasties (as well as metal containing conventional arthroplasties).
3. Pathomechanisms of local and systemic distribution of metal particles, ions and metallo-organic compounds
 - characterisation of wear products from joint articulations and taper interfaces;
 - influence of relevant parameters on wear and corrosion of taper connections;
 - correlations between the presence of wear / corrosion at taper connections and the presence / extent of ARMD;
 - mechanisms creating particles / ions / metallo-organic compounds or aggregates in bearings of different diameter;
 - systemic effects of an internal exposure to metal ions (i.e. Co, Cr) in contrast to external (industrial and environmental) exposure.
 - potential impact of additional metal ions (i.e. titanium).

4. Other relevant issues:

- prevalence of local and systemic adverse effects of MoM implants in joint registries;
- interaction between wear and corrosion of MoM interfaces;
- appropriate pre-clinical testing methods for metal implants (including biomechanic testing as well as in-vitro models) to investigate local and systemic consequences of metal particle release.

4.8. Research recommendations

4.8.1. Pre-clinical research

It is necessary to improve our knowledge on the particle release and especially the interaction of wear and corrosion from different categories (small-head and large-head MoM THA, HRA) as well as parts of implants (i.e. stem, taper junction, bearing surfaces). In addition, it is mandatory to understand more of the different regulatory mechanisms in implant marketing and introduction into clinical practice.

Suggestions for research:

- 1) Investigate the influence of relevant parameters on wear and corrosion of taper connections (taper size, diameter and length), material, texture, head diameter, joint articulation friction, assembly forces and direction. Wear products from taper interfaces and joint articulation should be characterised, if possible.
- 2) Determine the mechanisms creating particles / ions / metallo-organic compounds or aggregates in large ($\geq 36\text{mm}$) and small ($< 36\text{mm}$) MoM bearings functioning under ideal and suboptimal conditions. The distribution of nano-particles should be determined.
- 3) Determine the potential impact of additional metal ions (i.e. titanium).
- 4) Investigate the interaction between wear and corrosion of MoM interfaces and develop appropriate pre-clinical testing methods; means (by design or metallurgy) to avoid synergistic corrosion effects should be identified.
- 5) Establish *in vitro* models to investigate local and systemic consequences of metal debris (i.e. 3-Dscaffolds).
- 6) Perform further studies of the biology of the exposure using experimental animal systems. It would be important to test the relative effects of exposure to particles, ions and metal complexes trying wherever possible to recreate the modes of wear that are seen in vivo (including corrosion and impingement).
- 7) Perform studies on improved metal to tissue interfaces.
- 8) Study the effects of different regulatory requirements in different countries upon the introduction of new implants on the market.

4.8.2. Clinical research

Currently, the main gaps of knowledge concern the frequency and the clinical relevance (including pathomechanisms) of adverse local and systemic effects of an internal exposure to metal ions. The most important and clinically relevant questions to answer are:

- 1) What is the biological reaction to periprosthetic local as well systemic exposure to metal particles and ions?

- 2) What are the systemic effects of different metal products in different organs?
- 3) Is there an increased risk of cancer from all types of metal implants and especially MoM implants?
- 4) When and how should revisions of MoM implants be performed?
- 5) Do non-surgical alternatives exist?

Suggestions for research:

- 1) Perform studies in patient samples at sites where cancer risk has been highlighted (bladder, kidney skin, bone marrow, blood, prostate). Test whether there are potential mutagenic or even precancerous changes in cells at possible risk of metal exposure (i.e. melanocytes). Perform correlations of these changes with metal accumulation at these sites to test whether there might be any relation with exposure.
- 2) Continue to follow-up patients using modern epidemiology, wherever possible subdividing patients according to the levels of their exposures, type of implant, performance of the implant e.g. revision surgery and whether the patients have specific diseases which might act as confounding variables. It is necessary to determine the true incidence as well as clinical relevance of ARMD in all categories of MoM implants.
- 3) Determine metal ion levels after the implantation of any kind of artificial implant (i.e. knee arthroplasty, spine implants and osteosynthesis devices) and to investigate associations with clinical symptoms.
- 4) Systematically examine, upon revision of MoM implants, the correlations between the presence of wear / corrosion at taper connections and the presence / extent of adverse local tissue reactions (i.e. necrosis, pseudotumour).
- 5) Correlate the changes found in preclinical *in vitro* studies and animal models with those found in clinical investigations (i.e. imaging, body fluid analysis) and autopsy.
- 6) Establish an "Autopsy bank" with post-mortem samples of different tissues (brain, heart, lung, kidney, liver, spleen, lymph node, skin) as well as urine and blood at autopsy.
- 7) Perform comparative tests to investigate urine as a screening tool.
- 8) Identify issues concerning the reproducibility of metal ion measurements among different labs.

4.8.3. Post-market studies

It is necessary to establish a traceability system to follow-up potential adverse events in MoM implant patients. The infrastructure of partly-existing hip arthroplasty registries in different European countries could be used for this purpose.

Suggestions for research:

- 1) Establish Hip Arthroplasty Registers with better documentation of reasons for revision.
- 2) Health service research regarding appropriateness of regular follow-up investigations in MoM-patients including reimbursement issues in order to establish risk-benefit calculations.

5. OPINION

A summary of the scientific rationale can be found in section 1. Executive Summary.

Terms of reference and answers

Q1: To determine the short, medium and long term local and systemic health effects caused by metal particles, metal ions, metallo-organic compounds resulting from the implanted medical device and if possible to provide indications on limit values for the metals in any forms.

Metal-on-Metal (MoM) hip arthroplasty leads to a release of metal products (e.g. particles and ions) which can in addition form metallo-organic compounds in the body. These products can subsequently be deposited in draining lymph nodes and internal organs. This may result in local and systemic adverse health effects. However, it is not possible to determine whether these are due to metal particles, ions or metallo-organic compounds released from the implants.

Local tissue reactions: The local responses can be described as consisting of a broad clinical spectrum ranging from small asymptomatic tissue lesions to severe destruction of bone and soft tissues. These lesions are designated by different terminologies such as: metallosis, ALVAL (aseptic lymphocytic vasculitis associated lesion), pseudotumours and ARMD (adverse reactions to metal debris). These local responses can be diagnosed at any time after surgery (short-, medium- and long- term). Based on follow-up studies, a threshold value for clinical concern is expected to be within the range of 2 to 7 µg/L (exact levels have still to be determined within this range).

Systemic adverse responses: The application of toxicology data from either animal studies or occupational studies for evaluation of adverse effects of metals in patients with MoM hip arthroplasties is currently limited because the degradation products are not adequately characterised. Therefore, the observations in various animal studies cannot be extrapolated to the internal exposure as seen by release of metals from MoM implants. There are some specific concerns related to the possible systemic exposure to cobalt and/or chromium after MoM-hip arthroplasty such as systemic organ toxicity, carcinogenicity and teratogenicity. Although some papers indicate systemic organ effects and an increase in tumour rate, the evidence is insufficient and needs further confirmation. Currently, no distinction between short, medium and long term systemic effects is possible. Regarding teratogenicity, potential transplacental passage of metal ions has been demonstrated in the absence of any teratogenic effect up to now.

Two different categories of MoM arthroplasties have to be differentiated: Total Hip Arthroplasty THA with either small (head diameter < 36 mm) or large-heads (head diameter ≥ 36 mm), and Resurfacing Hip Arthroplasty (HR, always large-head diameter). The described adverse health effects apply to all types of these MoM hip arthroplasties. MoM arthroplasty with large diameters (resurfacing and especially large-head MoM THA) show the highest incidence of local reactions. For systemic health effects, no association with the type of implant or diameter has been established up to now. Local as well as systemic adverse effects can also occur with other types of metallic implants (e.g. plates, screws).

Critical values for systemic effects have not yet been established for patients after MoM implantation, mainly due to the lack of data.

Q2: To advise on the predictive value of metal ions in body fluids, clinical strategies and other aspects needed to ensure the safety of implanted patients. Criteria that should inform the medical decision with respect to the implanted patient should be identified where possible.

Based on the current information, no exact values of critical metal ions thresholds can be given for clinical decision-making regarding clinical follow-up. The SCENIHR decided to adopt the strategy as outlined in the European Consensus Statement. This strategy includes recommendations on technical issues (e.g. metal ion determination for screening purposes should be performed in whole blood) and determination of critical threshold ranges (e.g. for Co a range of 2 to 7 µg/L Co whole blood was defined).

One of these recommendations concerns systematic follow-up for all patients and all implants due to the risks of MoM bearings. For small-head MoM THA, a systematic follow-up comparable to conventional THA is sufficient. A closer follow-up is recommended, however, for large-head MoM THA (annual follow-up for the life of the joint) as well as HRA. For the latter, annual follow-up for at least the first five years is recommended, and then it may be changed to local protocols for patients with conventional THA (if metal ion levels are not significantly elevated). Another recommendation refers to HRA-patients with special risk factors (i.e. small component size, female gender, low coverage arc) for whom annual follow-up for the lifetime of the joint is recommended. However, all patients should undergo clinical as well as radiographic examination during follow-up. Metal ion determination is currently recommended for large-head MoM THA on a routine basis and for HRA patients at least in the first postoperative years (thereafter it may depend on their clinical performance. In case of clinical and/or radiographic abnormality and significantly elevated metal ion levels (i.e. metal ion values above a certain threshold, which is currently within the range of 2 to 7 µg/L Cobalt-concentration), additional imaging (ultrasound, CT-scan, and/or MARS-MRI) is recommended. Metal ion determination for screening purposes should be performed in whole blood. Cobalt can serve as reference substance.

Importantly, these recommendations are based on potential local adverse effects of MoM arthroplasties, because critical values for systemic effects have not yet been established.

Q3: To identify criteria regarding the safety and safe use of MoM implants used in arthroplasty, paying special attention to design and patient groups.

The application of MoM hip arthroplasty should be carefully considered on a case-by-case basis, due to the potential adverse effects of released metal, especially in certain subgroups of patients.

All types of MoM implants are contraindicated, for example, in females of childbearing age and in patients who are allergic to relevant metals. MoM HRA should not be performed in females with small femoral head size. In carefully selected young and active male patients with large femoral head size and favourable large head-neck-ratio, however, HRA can be an alternative to conventional THA.

The choice of the type of implant should be based on a detailed case-by-case evaluation taking into account all risks and benefits. The patient should be informed about the specific adverse effects related to MoM implants and should be followed up rigorously.

Finally, the procedure – the placing – should be performed by very experienced surgeons to reduce the risk of incorrect positioning to a minimum.

The MoM experience indicates that the stepwise introduction of new implants types, even if similar to those in use in the market, should be accompanied by proper pre-clinical and clinical studies. The regulatory approval by the Notified Bodies in Europe should not be based on the acceptance of minimal design changes.

Q4: Where relevant to identify needs for further research.

For additional safety evaluation, data on internal exposure in animal toxicity studies is necessary for comparison with exposures occurring in patients who received MoM arthroplasty.

Further research is necessary to clarify which components of metallic debris are responsible for the local and/or systemic adverse reactions.

Further research is necessary to investigate the contribution of the bearing and the taper interface to the production of metallic debris. The taper interface should also be the focus of further research including other bearing articulations.

Prospective studies should be made into the relationship between patients metal levels and clinical outcome. This research should include standardised reliable methodology for metal determination.

Research into local and systemic reactions in post-mortem samples including determination of metals and their various combinations.

Research into the possible role of other metals than Co and Cr such as Ti and V, in view of the inconsistency in relationship between the clinical outcome and Co/Cr metal ion levels. In addition, research is needed to replace the metals by other "hard", stable and low hazardous materials (i.e. ceramic implants).

Determine the incidence and prevalence of adverse local and systemic health effects in patients with MoM hip arthroplasties by setting up mandatory national registries providing the required data. This requirement should be applied to all permanent implants.

6. CONSIDERATION OF THE RESPONSES RECEIVED DURING THE CONSULTATION PROCESS

A public consultation on this opinion was opened on the website of the non-food scientific committees from 13 March to 25 April 2014. Information about the public consultation was broadly communicated to national authorities, international organisations and other stakeholders.

Fourteen organisations and individuals participated in the public consultation providing 51 comments to different chapters and section of the opinion. Each comment was carefully considered by the Working Group, and the scientific opinion has been revised to take account of relevant comments. The literature has been accordingly updated with relevant publications. The scientific rationale and the opinion section were clarified and strengthened.

The text of the comments received and the response provided by the SCENIHR is available here:

http://ec.europa.eu/health/scientific_committees/consultations/public_consultations/scenih_r_consultation_20_en.htm

7. MINORITY OPINION

None

8. LIST OF ABBREVIATIONS

| | |
|-----------|--|
| Ag: | Silver |
| Al: | Aluminium |
| ALVAL: | Aseptic lymphocytic vasculitis associated lesion |
| ARMD: | Adverse reactions to metal debris |
| CoC: | Ceramic-on-Ceramic |
| CoP: | Ceramic-on-Polyethylene |
| Co: | Cobalt |
| Cr: | Chromium |
| CrCN: | Chromium carbon nitride |
| CrN: | Chromium nitride |
| CT: | Computed Tomography |
| Cu: | Copper |
| Fe: | Iron |
| HRA: | Hip resurfacing arthroplasty |
| MARS-MRI: | Metal Artifact Reduction Sequence - Magnetic Resonance Imaging |
| Mo: | Molybdenum |
| Mn: | Manganese |
| MoM: | Metal-on-Metal |
| MoP: | Metal-on-Polyethylene |
| MRI: | Magnetic Resonance Imaging |
| Ni: | Nickel |
| QoL: | Quality-of-Life |
| Si: | Silicon |
| THA: | Total hip arthroplasty |
| Ti: | Titanium |
| TiN: | titanium nitride |
| TiNbN | titanium niobium nitride |
| US: | Ultrasound |
| µg/L: | Microgram per litre |
| V: | Vanadium |

9. REFERENCES

- Afssaps, Agence française de sécurité sanitaire des produits de santé. Prothèses de hanche ASR du fabricant DePuy rappelées en juillet 2010. Recommandations de l'Afssaps. 2012. <http://ansm.sante.fr/content/download/39685/518877/version/3/file/pi-120229-protheses-DePuy.pdf> (checked November 2012).
- Amstutz HC, Le Duff MJ, Campbell PA, Gruen TA, Wisk LE (2010) Clinical and radiographic results of Metal-on-Metal hip resurfacing with a minimum ten-year follow-up. *J Bone Joint Surg Am* 92(16):2663-71
- Anderson H, Toms AP, Cahir JG, Goodwin RW, Wimhurst J, Nolan JF. Grading the severity of soft tissue changes associated with Metal-on-Metal hip replacements: reliability of an MR grading system. *Skeletal Radiol.* 2011 Mar;40(3):303-7. Epub 2010 Jul 25.
- Aqil A, Drabu R, Bergmann JH, Masjedi M, Manning V, Andrews B, Muirhead-Allwood SK, Cobb JP. The gait of patients with one resurfacing and one replacement hip: a single blinded controlled study. *Int Orthop.* 2013 May;37(5):795-801. doi: 10.1007/s00264-013-1819-3. Epub 2013 Feb 27.
- Australian Orthopaedic Association National Joint Replacement Registry. Annual report 2011. Published October 2011 and since then available at: www.dmac.adelaide.edu.au/aoanjrr/publications.jsp. Accessed October 15, 2011.
- Australian Orthopaedic Association National Joint Replacement Registry (2012) Hip and Knee Arthroplasty - Annual Report 2012. <https://aoanjrr.dmac.adelaide.edu.au/documents/10180/60142/Annual%20Report%202012?version=1.2&t=1355186837517>
- Baan, R. A. Carcinogenic hazards from inhaled carbon black, titanium dioxide, and talc not containing asbestos or asbestiform fibers: recent evaluations by an IARC Monographs Working Group. *Inhal. Toxicol.* 2007, 19 Suppl 1, 213-228.
- Ball ST, Le Duff MJ, Amstutz HC (2007) Early results of conversion of a failed femoral component in hip resurfacing arthroplasty. *J Bone Joint Surg Am* 89(4):735-41
- Baur W, Honle W, Willert HG, Schuh A (2005) [Pathological findings in tissue surrounding revised metal/metal articulations]. *Orthopade* 34(3):225-233
- Benedetti MG, Berti L, Frizziero A, Ferrarese D, Giannini S. Functional recovery after hip resurfacing and rehabilitation. *J Sport Rehabil.* 2012 May;21(2):167-74.
- Beraudi A, Montesi M, Stea S, Sudanese A, Apostoli P, Toni A. Detection of cobalt in synovial fluid from metal-on-metal hip prosthesis: correlation with the ionic haematic level. *Biomarkers* 2013: Early Online 1-7. doi:10.3109/1354750X.2013.846413
- Bermudez, E.; Mangum, J. B.; Asgharian, B.; Wong, B. A.; Reverdy, E. E.; Janszen, D. B.; Hext, P. M.; Warheit, D. B.; Everitt, J. I. Long-term pulmonary responses of three laboratory rodent species to subchronic inhalation of pigmentary titanium dioxide particles. *Toxicological Sciences* 2002, 70 (1), 86-97.
- Bermudez, E.; Mangum, J. B.; Wong, B. A.; Asgharian, B.; Hext, P. M.; Warheit, D. B.; Everitt, J. I. Pulmonary responses of mice, rats, and hamsters to subchronic inhalation of ultrafine titanium dioxide particles. *Toxicol. Sci.* 2004, 77 (2), 347-357.
- BHS. BHS statements on large diameter metal on metal bearing total hip replacements. 2012. <http://www.britishhipsociety.com/uploaded/BHS MOM THR.pdf> (checked November 2012).
- Bisschop R, Boomsma MF, Van Raay JJAM, Tiebosch ATMG, Maas M, Gerritsma CLE. High Prevalence of Pseudotumours in Patients with a Birmingham Hip Resurfacing Prosthesis. A Prospective Cohort Study of One Hundred and Twenty-nine Patients. *J Bone Joint Surg Am.* 2013;95:1554-6
- Bjorgul K, Novicoff WN, Andersen ST, Ahlund OR, Bunes A, Wiig M, Brevig K. High rate of revision and a high incidence of radiolucent lines around Metasul metal-on-metal total hip

replacements: results from a randomised controlled trial of three bearings after seven years. *Bone Joint J.* 2013 Jul;95-B(7):881-6.

Boffetta, P.; Gaborieau, V.; Nadon, L.; Parent, M. E.; Weiderpass, E.; Siemiatycki, J. Exposure to titanium dioxide and risk of lung cancer in a population-based study from Montreal. *Scandinavian Journal of Work Environment & Health* 2001, 27 (4), 227-232.

Boffetta, P.; Soutar, A.; Cherrie, J. W.; Granath, F.; Andersen, A.; Anttila, A.; Blettner, M.; Gaborieau, V.; Klug, S. J.; Langard, S.; Luce, D.; Merletti, F.; Miller, B.; Mirabelli, D.; Pukkala, E.; Adami, H. O.; Weiderpass, E. Mortality among workers employed in the titanium dioxide production industry in Europe. *Cancer Causes Control* 2004, 15 (7), 697-706.

Bolland BJ, Culliford DJ, Langton DJ, Millington JP, Arden NK, Latham JM (2011) High failure rates with a large-diameter hybrid Metal-on-Metal total hip replacement: clinical, radiological and retrieval analysis. *J Bone Joint Surg Br* 93(5):608-615

Boomsma MF, H B Ettema and C Van Der Straeten, The hip resurfacing handbook: A practical guide to the use and management of modern hip resurfacings. PART 2 CLINICAL FOLLOW-UP The use of Computerized Tomography (CT) to evaluate hip resurfacing. Edited by K De Smet, ANCA Clinic, Belgium, P Campbell, UCLA, USA and C Van Der Straeten, Consultant, Belgium <http://www.woodheadpublishing.com/en/book.aspx?bookID=2090>

Bosker BH, Ettema HB, Boomsma MF, Kollen BJ, Maas M, Verheyen CC (2012) High incidence of pseudotumour formation after large-diameter Metal-on-Metal total hip replacement: a prospective cohort study. *J Bone Joint Surg Br* 94(6):755-61

Brewster DH, Stockton DL, Reekie A, Ashcroft GP, Howie CR, Porter DE, Black RJ. Risk of cancer following primary total hip replacement or primary resurfacing arthroplasty of the hip: a retrospective cohort study in Scotland. *Br J Cancer.* 2013 May 14;108(9):1883-90. doi: 10.1038/bjc.2013.129. Epub 2013 Apr 2

Brodner W, Bitzan P, Meisinger V, Kaider A, Gottsauner-Wolf F, Kotz R. Serum cobalt levels after metal-on-metal total hip arthroplasty. *J Bone Joint Surg Am.* 2003;85:2168-73.

Brodner W, Grohs JG, Bancher-Todesca D, Dorotka R, Meisinger V, Gottsauner-Wolf F, Kotz R (2004) Does the placenta inhibit the passage of chromium and cobalt after Metal-on-Metal total hip arthroplasty? *J Arthroplasty* 19(8 Suppl 3):102-106

Canadian Arthroplasty Society. The Canadian Arthroplasty Society's experience with hip resurfacing arthroplasty. An analysis of 2773 hips. *Bone Joint J.* 2013 Aug;95-B(8):1045-51

Chang EY, McAnally JL, Van Horne JR, Statum S, Wolfson T, Gamst A, Chung CB. Metal-on-metal total hip arthroplasty: do symptoms correlate with MR imaging findings? *Radiology.* 2012 Dec;265(3):848-57. doi: 10.1148/radiol.12120852. Epub 2012 Oct 9

Chen Z, Pandit H, Taylor A, Gill H, Murray D, Ostlere S. Metal-on-metal hip resurfacings—a radiological perspective. *Eur Radiol.* 2011 Mar;21(3):485-91. Epub 2010 Sep 15.

Chen Z, Wang Z, Wang Q, Cui W, Liu F, Fan W. Changes in Early Serum Metal Ion Levels and Impact on Liver, Kidney, and Immune Markers Following Metal-on-Metal Total Hip Arthroplasty. *J Arthroplasty.* 2013 Aug 27. pii: S0883-5403(13)00549-4. doi: 10.1016/j.arth.2013.07.031. [Epub ahead of print]

Chen, J. L.; Fayerweather, W. E. Epidemiologic-Study of Workers Exposed to Titanium-Dioxide. *Journal of Occupational and Environmental Medicine* 1988, 30 (12), 937-942.

Consensus statement "Current Evidence on the Management of Metal-on-Metal Bearings". http://www.efort.org/communications/pdf/2012_05_10_MoM_Consensus_statement.pdf

Cousen PJ, Gawkrödger DJ. Metal allergy and second-generation metal-on-metal arthroplasties. *Contact Dermatitis.* 2012 Feb;66(2):55-62. doi: 10.1111/j.1600-0536.2011.01970.x. Epub 2011 Sep 29.

Cuckler JM, Moore KD, Lombardi AV, Jr., McPherson E, Emerson R (2004) Large versus small femoral heads in Metal-on-Metal total hip arthroplasty. *J Arthroplasty* 19(8 Suppl 3):41-4

- Daniel J, Holland J, Quigley L, Sprague S, Bhandari M (2012) Pseudotumours associated with total hip arthroplasty. *J Bone Joint Surg Am.* 94(1): 86-93
- Daniel J, Ziaee H, Kamali A, Pradhan C, Band T, McMinn DJ (2010) Ten-year results of a double-heat-treated Metal-on-Metal hip resurfacing. *J Bone Joint Surg Br* 92(1):20-7
- Daniel J, Ziaee H, Pradhan C, McMinn DJ. Six-year results of a prospective study of metal ion levels in young patients with Metal-on-Metal hip resurfacings. *J Bone Joint Surg Br* 2009;91:176-179.
- Daniel J, Ziaee H, Pradhan C, Pynsent PB, McMinn DJ (2010) Renal clearance of cobalt in relation to the use of Metal-on-Metal bearings in hip arthroplasty. *J Bone Joint Surg Am* 92(4):840-845
- De Haan R, Campbell PA, Su EP, De Smet KA. Revision of metal-on-metal resurfacing arthroplasty of the hip: the influence of malpositioning of the components, *J Bone Joint Surg Br.* 2008;90(9):1158-63
- De Haan R, Pattyn C, Gill HS, Murray DW, Campbell PA, De Smet K. Correlation between inclination of the acetabular component and metal ion levels in Metal-on-Metal hip resurfacing replacement. *J Bone Joint Surg Br.* 2008;90:1291-1297.
- De Pasquale D, Stea S, Squarzone S, Bordini B, Amabile M, Catalani S, Apostoli P, Toni A. Metal-on-metal hip prostheses: Correlation between debris in the synovial fluid and levels of cobalt and chromium ions in the bloodstream. *Int Orthopaedics* 2013; On-line first (Oct) 10.1007/s00264-013-2137-
- De Smet K, De Haan R, Calistri A, Campbell PA, Ebrahimzadeh E, Pattyn C, Gill HS. Metal ion measurement as a diagnostic tool to identify problems with Metal-on-Metal hip resurfacing. *J Bone Joint Surg Am.* 2008;90(Suppl 4):202-208.
- De Smet K, Van Der Straeten C, Van Orsouw M, Doubi R, Backers K, Grammatopoulos G. Revisions of Metal-on-Metal Hip Resurfacing: Lessons Learned and Improved Outcome. *Orthopedic Clinics of North America* 42, April 2011, 259-269.
- De Smet KA, Van Der Straeten C. Revisions of Metal-on-Metal hip resurfacing: causes, treatment options and improved outcome. *Minerva Ortopedica e Traumatologica* 2012; 63:111-23.
- deSouza RM, Wallace D, Costa ML, Krikler SJ (2012) Transplacental passage of metal ions in women with hip resurfacing: no teratogenic effects observed. *Hip Int* 22(1):96-99
- Desy NM, Bergeron SG, Petit A, Huk OL, Antoniou J. Surgical variables influence metal ion levels after hip resurfacing. *Clin Orthop Relat Res* 2011;469:1635-1641.
- Duggan PJ, Burke CJ, Saha S, Moonim M, George M, Desai A, Houghton R. Current literature and imaging techniques of aseptic lymphocyte-dominated vasculitis-associated lesions (ALVAL). *Clin Radiol.* 2013 Nov;68(11):1089-96. doi: 10.1016/j.crad.2013.04.017. Epub 2013 Aug 6.
- Dunstan E, Ladon D, Whittingham-Jones P, Carrington R, Briggs TW (2008) Chromosomal aberrations in the peripheral blood of patients with Metal-on-Metal hip bearings. *J Bone Joint Surg Am* 90(3):517-522
- Dutch Orthopaedic Association. The use of Metal-on-Metal hip replacements: More strict advice to NOV members, 17January 2012. <http://www.orthopeden.org/uploads/UT/Eh/UTEhC1OA 0-mRSJTfROfA/Advice-NOV-on-the-use-of-MoM-hip-replacements-17-01-2012.pdf> (checked November 2012).
- Engh CA, Jr., Ho H, Engh CA (2010) Metal-on-metal hip arthroplasty: does early clinical outcome justify the chance of an adverse local tissue reaction? *Clin Orthop Relat Res* 468(2):406-12
- Estey MP, Diamandidis E, Van Der Straeten C, Hart A, Tower S, Moyer T, Cobalt and Chromium Measurement in Patients with Metal Hip Prostheses. *Clin Chem.* 2012 Oct 31. [Epub ahead of print] ID# CLINCHEM/2012/193037:

Eswaramoorthy V, Moonot P, Kalairajah Y, Biant LC, Field RE (2008) The Metasul Metal-on-Metal articulation in primary total hip replacement: clinical and radiological results at ten years. *J Bone Joint Surg Br* 90(10):1278-1283

Food and Drug Administration. FDA 522 guidance document. Available at: www.fda.gov/downloads/MedicalDevices/DeviceRegulationandGuidance/GuidanceDocuments/ucm072564.pdf. Accessed August 16, 2011.

Fryzek, J. P.; Chadda, B.; Marano, D.; White, K.; Schweitzer, S.; McLaughlin, J. K.; Blot, W. J. A cohort mortality study among titanium dioxide manufacturing workers in the United States. *J. Occup. Environ. Med.* 2003, 45 (4), 400-409.

Garabrant, D. H.; Fine, L. J.; Oliver, C.; Bernstein, L.; Peters, J. M. Abnormalities of pulmonary function and pleural disease among titanium metal production workers. *Scand. J. Work Environ. Health* 1987, 13 (1), 47-51.

Garbuz DS, Tanzer M, Greidanus NV, Masri BA, Duncan CP. The John Charnley Award: Metal-on-metal hip resurfacing versus large-diameter head Metal-on-Metal total hip arthroplasty: a randomized clinical trial. *Clin Orthop Relat Res.* 2010;468: 318-325.

Garbuz DS, Hargreaves BA, Duncan CP, Masri BA, Wilson DR, Forster BB. . The John Charnley Award: Diagnostic Accuracy of MRI Versus Ultrasound for Detecting s in Asymptomatic Metal-on-Metal THA. *Clin Orthop Relat Res.* 2013 Jul 19. [Epub ahead of print]

Gill HS, Grammatopoulos G, Adshead S, Tsialogiannis E, Tsiridis E., Molecular and immune toxicity of CoCr nanoparticles in MoM hip arthroplasty, *Trends Mol Med.* 2012 Mar;18(3):145-55

Glyn-Jones S, Pandit H, Kwon YM, Doll H, Gill HS, Murray DW. Risk factors for inflammatory pseudotumour formation following hip resurfacing. *J Bone Joint Surg [Br]* 2009;91-B:1566-74.

Grammatopolous G, Pandit H, Kwon YM, Gundle R, McLardy-Smith P, Beard DJ, Murray DW, Gill HS., Hip resurfacings revised for inflammatory pseudotumour have a poor outcome, *J Bone Joint Surg Br.* 2009;91(8):1019-24.

Griffin WL, Fehring TK, Kudrna JC, Schmidt RH, Christie MJ, Odum SM, Denny AC. Are metal ion levels a useful trigger for surgical intervention? *J Arthroplasty.* 2012 Sep;27(8 Suppl):32-6

Griffin WL, Nanson CJ, Springer BD, Fehring TK. Reduced articular surface of one-piece cups: a cause of runaway wear and early failure. *Clin Orthop Relat Res.* 2010;468:2328-2332.

Gruber FW, Bock A, Trattnig S, Lintner F, Ritschl P (2007) Cystic lesion of the groin due to metallosis: a rare long-term complication of Metal-on-Metal total hip arthroplasty. *J Arthroplasty* 22(6):923-927

Grubl A, Marker M, Brodner W, Giurea A, Heinze G, Meisinger V, Zehetgruber H, Kotz R (2007) Long-term follow-up of Metal-on-Metal total hip replacement. *J Orthop Res* 25(7):841-848

Günther KP, Schmitt J, Campbell P, Delaunay CP, Drexler H, Ettema HB, García-Cimbrelo E, Hannemann F, Hartmann A, Huberti H, Knahr K, Kunze J, Langton DJ, Lauer W, Learmonth I, Lohmann CH, Lützner J, Morlock M, Seidler A, Wimmer MA, Zagra L. Consensus statement "Current evidence on the management of metal-on-metal bearings" - April 16, 2012. *Hip Int.* 2013 Feb 21;23(1):2-5. doi: 10.5301/HIP.2013.10754.

Günther KP, Lützner J, Hannemann F, Schmitt J, Kirschner S, Goronzy J, Stiehler M, Lohmann C, Hartmann A. Update on metal-on-metal hip joints. *Orthopade.* 2013 May;42(5):373-87; quiz 388-9. doi: 10.1007/s00132-013-2100-6. German

Haddad FS, Thakrar RR, Hart AJ, Skinner JA, Nargol AV, Nolan JF, Gill HS, Murray DW, Blom AW, Case CP. Metal-on-metal bearings: the evidence so far. *J Bone Joint Surg Br.* 2011; 93:572-579.

Hannemann F, Hartmann, A Schmitt J, Lützner J, Seidler A, Campbell P, Delaunay CP, Drexler H, Ettema HB, García-Cimbrelo E, Huberti H, Knahr K, Kunze J, Langton DJ, Lauer W, Learmonth I, Lohmann CH, , Morlock M, Wimmer MA, Zagra L. Günther KP. European multidisciplinary consensus statement on the use and monitoring of metal-on-metal bearings

for total hip replacement and hip resurfacing. *Orthopaedics & Traumatology: Surgery & Research* (2013)

Hart AJ, Sabah SA, Bandi AS, Maggiore P, Tarassoli P. Sensitivity and specificity of blood cobalt and chromium metal ions for predicting failure of MoM hip replacement. *JBJS Br* 2011; 93-B: 1308-1313.

Hart AJ, Skinner JA, Henckel J, Sampson B, Gordon F. Insufficient acetabular version increases blood metal ion levels after Metal-on-Metal hip resurfacing. *Clin Orthop Relat Res* 2011;469:2590-2597.

Hart AJ, Satchithananda K, Liddle AD, Sabah SA, McRobbie D, Henckel J, Cobb JP, Skinner JA, Mitchell AW. Pseudotumors in association with well-functioning metal-on-metal hip prostheses: a case control study using three-dimensional computed tomography and magnetic resonance imaging. *J Bone Joint Surg Am* 2012;94:317e25

Hartmann A, Hannemann F, Lützner J, Seidler A, Drexler H, Günther KP, Schmitt J. Metal ion concentrations in body fluids after implantation of hip replacements with metal-on-metal bearing -- systematic review of clinical and epidemiological studies. *PLoS One*. 2013;8(8):e70359. doi: 10.1371/journal.pone.0070359. eCollection 2013

Hartmann A, Lutzner J, Kirschner S, Witzleb WC, Gunther KP (2012) Do Survival Rate and Serum Ion Concentrations 10 Years After Metal-on-Metal Hip Resurfacing Provide Evidence for Continued Use? *Clin Orthop Relat Res* 470(11):3118-26

Health Products and Food Branch Inspectorate HC. Important safety information regarding metal-on-metal hip implant surgery. April 11, 2012. http://www.hc-sc.gc.ca/dhp-mps/alt_formats/pdf/medeff/advisories-avis/prof/2012/metal_implant_hpc-cps-eng.pdf (checked November 2012).

Heinrich, U.; Fuhst, R.; Rittinghausen, S.; Creutzenberg, O.; Bellmann, B.; Koch, W.; Levsen, K. Chronic Inhalation Exposure of Wistar Rats and 2 Different Strains of Mice to Diesel-Engine Exhaust, Carbon-Black, and Titanium-Dioxide. *Inhalation Toxicology* 1995, 7 (4), 533-556.

Heisel C, Streich N, Krachler M, Jakubowitz E, Kretzer JP. Characterization of the running-in period in total hip resurfacing arthroplasty: an in vivo and in vitro metal ion analysis. *J Bone Joint Surg Am*. 2008;90:125-133.

Hext, P. M.; Tomenson, J. A.; Thompson, P. Titanium dioxide: inhalation toxicology and epidemiology. *Ann. Occup. Hyg.* 2005, 49 (6), 461-472.

Hur CI, Yoon TR, Cho SG, Song EK, Seon JK (2008) Serum ion level after Metal-on-Metal THA in patients with renal failure. *Clin Orthop Relat Res* 466(3):696-699

Jantzen C, Jørgensen HL, Duus BR, Sporing SL, Lauritzen JB. Chromium and cobalt ion concentrations in blood and serum following various types of metal-on-metal hip arthroplasties: a literature overview. *Acta Orthop.* 2013 Jun;84(3):229-36. doi: 10.3109/17453674.2013.792034. Epub 2013 Apr 18

Johnson AJ, Woon RP, Le Duff MJ, Amstutz HC. Childhood development after maternal metal-on-metal hip resurfacing. *Hip Int.* 2013 Mar-Apr;23(2):181-6. doi: 10.5301/HIP.2013.10731. Epub 2013 Feb 12.

Joyce TJ, Grigg H, Langton DJ, Nargol AVF: Quantification of self-polishing in vivo from explanted metal-on-metal total hip replacements. *Tribology International* 2011; 44 (5):513-516.

Keegan GM, Learmonth ID, Case CP (2007) Orthopaedic metals and their potential toxicity in the arthroplasty patient: A review of current knowledge and future strategies. *J Bone Joint Surg Br* 89(5):567-573

Korovessis P, Petsinis G, Repanti M, Repantis T (2006) Metallosis after contemporary Metal-on-Metal total hip arthroplasty. Five to nine-year follow-up. *J Bone Joint Surg Am* 88(6):1183-1191

- Kwon YM, Ostlere SJ, McLardy-Smith P, Athanasou NA, Gill HS, Murray DW. 'Asymptomatic' pseudotumors after metal-on-metal hip resurfacing arthroplasty: prevalence and metal ion study. *J Arthroplasty*. 2011;26:511-518.
- Kwon YM, Thomas P, Summer B, Pandit H, Taylor A, Beard D, Murray DW, Gill HS (2010) Lymphocyte proliferation responses in patients with pseudotumors following Metal-on-Metal hip resurfacing arthroplasty. *J Orthop Res* 28(4):444-450
- Langton DJ, Jameson SS, Joyce TJ, Gandhi JN, Sidaginamale R, Merredy P, Lord J, Nargol AV. Accelerating failure rate of the ASR total hip replacement. *J Bone Joint Surg Br* 2011;93:1011-1016.
- Langton DJ, Jameson SS, Joyce TJ, Hallab NJ, Natsu S, Nargol AV (2010) Early failure of Metal-on-Metal bearings in hip resurfacing and large-diameter total hip replacement: A consequence of excess wear. *J Bone Joint Surg Br* 92(1):38-46
- Langton DJ, Joyce TJ, Jameson SS, Lord J, Van OM, Holland JP, Nargol AV, De Smet KA. Adverse reaction to metal debris following hip resurfacing: the influence of component type, orientation and volumetric wear. *J Bone Joint Surg Br* 2011; 93(2):164-171
- Langton DJ, Sprowson AP, Joyce TJ, Reed M, Carlisle I, Partington P, Nargol AV. Blood metal ion concentrations after hip resurfacing arthroplasty: a comparative study of articular surface replacement and Birmingham Hip Resurfacing arthroplasties. *J Bone Joint Surg Br*. 2009;91:1287-1295.
- Langton DJ, Sidaginamale RP, Joyce TJ, Natsu S, Blain P, Jefferson RD, Rushton S, Nargol AV. The clinical implications of elevated blood metal ion concentrations in asymptomatic patients with MoM hip resurfacings: a cohort study. *BMJ Open*. 2013 Mar 12;3(3).
- Learmonth, I. D., Gheduzzi, S., Vail, T. P.: Clinical experience with Metal-on-Metal total joint replacements: indications and results. *Proc.Inst.Mech.Eng H*. 220, 229-237,(2006).
- Lee, K. P.; Trochimowicz, H. J.; Reinhardt, C. F. Pulmonary response of rats exposed to titanium dioxide (TiO₂) by inhalation for two years. *Toxicol. Appl. Pharmacol*. 1985, 79 (2), 179-192.
- Leikin JB, Karydes HC, Whiteley PM, Wills BK, Cumpston KL, Jacobs JJ. Outpatient toxicology clinic experience of patients with hip implants. *Clin Toxicol (Phila)*. 2013 May;51(4):230-6. doi:
- Li, J.; Li, Q.; Xu, J.; Li, J.; Cai, X.; Liu, R.; Li, Y.; Ma, J.; Li, W. Comparative study on the acute pulmonary toxicity induced by 3 and 20 nm TiO₂ primary particles in mice. *Environmental Toxicology and Pharmacology* 2007, 24 (3), 239-244.
- Liddle AD, Satchithananda K, Henckel J, Sabah SA, Vipulendran KV, Lewis A, Skinner JA, Mitchell AW, Hart AJ. Revision of metal-on-metal hip arthroplasty in a tertiary center: a prospective study of 39 hips with between 1 and 4 years of follow-up. *Acta Orthop*. 2013;84(3):237-45
- Lingard EA, Muthumayandi K, Holland JP. Comparison of patient-reported outcomes between hip resurfacing and total hip replacement. *J Bone Joint Surg [Br]* 2009;91-B:1550-4.
- Lombardi AV Jr, Barrack RL, Berend KR, Cuckler JM, Jacobs JJ, Mont MA, Schmalzried TP. The Hip Society: algorithmic approach to diagnosis and management of metal-on-metal arthroplasty. *J Bone Joint Surg Br*. 2012 Nov;94(11 Suppl A):14-8
- Mac Donald SJ, Brodner W, Jacobs JJ. A consensus paper on metal ions in Metal-on-Metal hip arthroplasties. *J Arthroplasty*. 2004;19(Suppl 3):12-16.
- Machado C, Appelbe A, Wood R. Arthroprosthetic cobaltism and cardiomyopathy. *Heart Lung Circ*. 2012 Nov;21(11):759-60. doi: 10.1016/j.hlc.2012.03.013. Epub 2012 Apr 18.
- Macnair RD, Wynn-Jones H, Wimbhurst JA, Toms A, Cahir J. Metal ion levels not sufficient as a screening measure for adverse reactions in metal-on-metal hip arthroplasties. *J Arthroplasty*. 2013 Jan;28(1):78-83. doi: 10.1016/j.arth.2012.05.029. Epub 2012 Jul 6.
- Malek IA, King A, Sharma H, Malek S, Lyons K, Jones S, John A. The sensitivity, specificity and predictive values of raised plasma metal ion levels in the diagnosis of adverse reaction to

metal debris in symptomatic patients with a metal-on-metal arthroplasty of the hip. *J Bone Joint Surg Br.* 2012 Aug;94(8):1045-50. doi: 10.1302/0301-620X.94B8.27626.

Makela KT, Visuri T, Pulkkinen P, Eskelinen A, Remes V, Virolainen P, Junnila M, Pukkala E (2012) Risk of cancer with Metal-on-Metal hip replacements: population based study. *BMJ* 345:e4646

Marker M, Grubl A, Riedl O, Heinze G, Pohanka E, Kotz R (2008) Metal-on-metal hip implants: do they impair renal function in the long-term? A 10-year follow-up study. *Arch Orthop Trauma Surg* 128(9):915-919

Matthies AK, Skinner JA, Osmani H, Henckel J, Hart AJ (2012) Pseudotumors are common in well-positioned low-wearing Metal-on-Metal hips. *Clin Orthop Relat Res* 470(7):1895-1906

McBryde CW, Theivendran K, Thomas A, Treacy R, Pynsent PB. The influence of head size and sex on the outcome of Birmingham Hip Resurfacing. *J Bone Joint Surg Am.* 2010;92:105-112.

Medical device alert of the Medicines and Healthcare products Regulatory Agency on all Metal-on-Metal (MoM) hip replacements. MDA/2010/033. Issued April 22, 2010. Available at: www.mhra.gov.uk/Publications/Safetywarnings/MedicalDeviceAlerts/CON079157. Accessed April 22, 2010.

Medicines and Healthcare Products Regulatory Agency (2012) Medical Device Alert: Metal-on-metal (MoM) hip replacements. MDA/2012/008. <http://www.mhra.gov.uk/home/groups/dts-bs/documents/medicaldevicealert/con143787.pdf>

Meyer H, Mueller T, Goldau G, Chamaon K, Ruetschi M, Lohmann CH (2012) Corrosion at the Cone/Taper Interface Leads to Failure of Large-diameter Metal-on-metal Total Hip Arthroplasties. *Clin Orthop Relat Res* 470(11):3101-3108

MHRA. Medical Device Alert. All metal-on-metal (MoM) hip replacements. 25 June 2012 <http://www.mhra.gov.uk/home/groups/dts-bs/documents/medicaldevicealert/con155767.pdf> (checked November 2012).

Milosev I, Trebse R, Kovac S, Cor A, Pisot V (2006) Survivorship and retrieval analysis of Sikomet Metal-on-Metal total hip replacements at a mean of seven years. *J Bone Joint Surg Am* 88(6):1173-1182

Mokka J, Junnila M, Seppänen M, Virolainen P, Pölönen T, Vahlberg T, Mattila K, Tuominen EK, Rantakokko J, Äärimaa V, Kukkonen J, Mäkelä KT. Adverse reaction to metal debris after ReCap-M2A-Magnum large-diameter-head metal-on-metal total hip arthroplasty. *Acta Orthop.* 2013 Oct 31. [Epub ahead of print]

Mokka J, Mäkelä KT, Virolainen P, Remes V, Pulkkinen P, Eskelinen A. Cementless Total Hip Arthroplasty with Large Diameter Metal-on-Metal Heads: Short-Term Survivorship of 8059 Hips from the Finnish Arthroplasty Register. *Scand J Surg.* 2013 Jun 1;102(2):117-23

Mont MA, Seyler TM, Ragland PS, Starr R, Erhart J, Bhav A. Gait analysis of patients with resurfacing hip arthroplasty compared with hip osteoarthritis and standard total hip arthroplasty. *J Arthroplasty.* 2007 Jan;22(1):100-8.

Morlock MM, Bishop N, Zustin J, Hahn M, Rüther W, Amling M. Modes of implant failure after hip resurfacing: morphological and wear analysis of 267 retrieval specimens. *J Bone Joint Surg Am.* 2008; Aug;90 Suppl 3:89-95.

Mueller LA, Schmidt R, Ehrmann C, Nowak TE, Kress A, Forst R, Pfander D. Modes of periacetabular load transfer to cortical and cancellous bone after cemented versus uncemented total hip arthroplasty: a prospective study using computed tomography-assisted osteodensitometry. *J Orthop Res.* 2009 Feb;27(2):176-82. doi: 10.1002/jor.20742

Muhle, H.; Bellmann, B.; Creutzenberg, O.; Koch, W.; Dasenbrock, C.; Ernst, H.; Mohr, U.; Morrow, P.; Mermelstein, R. Pulmonary response to toner, TiO₂ and crystalline silica upon chronic inhalation exposure in Syrian golden hamsters. *Inhalation Toxicology* 1998, 10 (7), 699-729.

- Munro JT, Masri BA, Duncan CP, Garbuz DS., High Complication Rate After Revision of Large-head Metal-on-metal Total Hip Arthroplasty., *Clin Orthop Relat Res*. 2013 Apr 10. [Epub ahead of print]
- Nawabi DH, Hayter CL, Su EP, Koff MF, Perino G, Gold SL, Koch KM, Potter HG. Magnetic resonance imaging findings in symptomatic versus asymptomatic subjects following metal-on-metal hip resurfacing arthroplasty. *J Bone Joint Surg Am*. 2013 May 15;95(10):895-902. doi: 10.2106/JBJS.K.01476.
- National Institute for Clinical Excellence. Guidance on the selection of prosthesis for primary total hip replacement (TA2). Available at <http://www.nice.org.uk> Accessed October 8, 2011
- National Joint Registry Annual report 2010.
<http://www.njrcentre.org.uk/njrcentre/Home/tabid/36/Default.aspx>
- National Joint Registry. Annual report 2011.
<http://www.njrcentre.org.uk/njrcentre/Home/tabid/36/Default.aspx>
- National Joint Registry. Annual report 2012;
<http://www.njrcentre.org.uk/njrcentre/Home/tabid/36/Default.aspx>
- National Joint Registry. Annual report 2013.
<http://www.njrcentre.org.uk/njrcentre/Home/tabid/36/Default.aspx>
- Natu S, Sidaginamale RP, Gandhi J, Langton DJ, Nargol AV (2012) Adverse reactions to metal debris: histopathological features of periprosthetic soft tissue reactions seen in association with failed metal on metal arthroplasties. *J Clin Pathol* 65(5): 409-418
- Nunley RM, Della Valle CJ, Barrack RL. Is patient selection important for hip resurfacing? *Clin Orthop Relat Res*. 2009;467: 56–65.
- Oldenburg M, Wegner R, Baur X. Severe cobalt intoxication due to prosthesis wear in repeated total hip arthroplasty. *J Arthroplasty*. 2009 Aug; 24(5):825.e15-20. doi: 10.1016/j.arth.2008.07.017. Epub 2008 Oct 2
- Onega T, Baron J, MacKenzie T. Cancer after total joint arthroplasty: a meta-analysis. *Cancer Epidemiol Biomarkers Prev*. 2006; 15:1532-7
- Ostlere S. How to image Metal-on-Metal prostheses and their complications. *AJR* 197:558–567
- Paustenbach DJ, Galbraith DA, Finley BL Interpreting cobalt blood concentrations in hip implant patients *Clinical Toxicology*, February 2014, Vol. 52, No. 2, Pages 98-112.
- Pandit H, Glyn-Jones S, McLardy-Smith P, Gundle R, Whitwell D, Gibbons CL, Ostlere S, Athanasou N, Gill HS, Murray DW. Pseudotumours associated with metal-on-metal hip resurfacings. *J Bone Joint Surg Br*. 2008;90:847–851.
- Park YS, Moon YW, Lim SJ, Yang JM, Ahn G, Choi YL (2005) Early osteolysis following second-generation Metal-on-Metal hip replacement. *J Bone Joint Surg Am* 87(7):1515-1521
- Pastides PS, Dodd M, Sarraf KM, Willis-Owen CA. Trunnionosis: A pain in the neck. *World J Orthop* 2013 October 18; 4(4): 161-166
- Petersen MK, Andersen NT, Mogensen P, Voight M, Søballe K. Gait analysis after total hip replacement with hip resurfacing implant or Mallory-head Exeter prosthesis: a randomised controlled trial. *Int Orthop*. 2011 May;35(5):667-74. doi: 10.1007/s00264-010-1040-6. Epub 2010 May 16.
- Pott, F.; Roller, M. Carcinogenicity study with nineteen granular dusts in rats. *Eur. J. Oncol*. 2005, 10, 249-281.
- Prentice JR, Clark MJ, Hoggard N, Morton AC, Tooth C, Paley MN, Stockley I, Hadjivassiliou M, Wilkinson JM. Metal-on-metal hip prostheses and systemic health: a cross-sectional association study 8 years after implantation. *PLoS One*. 2013 Jun 10;8(6):e66186
- Rahman, L., M. Hall-Craggs, and S. K. Muirhead-Allwood. "Radiology of the resurfaced hip." *Skeletal Radiol*. 40.7 (2011): 819-30.

- Rajpura A, Porter ML, Gambhir AK, Freemont AJ, Board TN, Clinical experience of revision of metal on metal hip arthroplasty for aseptic lymphocyte dominated vasculitis associated lesions (ALVAL), *Hip Int* 2010;21(1):43-51
- Ramanakumar, A. V.; Parent, M. E.; Latreille, B.; Siemiatycki, J. Risk of lung cancer following exposure to carbon black, titanium dioxide and talc: results from two case-control studies in Montreal. *Int. J. Cancer* 2008, 122 (1), 183-189.
- Renwick, L. C.; Brown, D.; Clouter, A.; Donaldson, K. Increased inflammation and altered macrophage chemotactic responses caused by two ultrafine particle types. *Occup. Environ. Med.* 2004, 61 (5), 442-447.
- Repantis T, Vitsas V, Koroivessis P. Poor mid-term survival of the low-carbide metal-on-metal Zweymüller-plus total hip arthroplasty system: a concise follow-up, at a minimum of ten years, of a previous report. *J Bone Joint Surg Am.* 2013 Mar 20;95(6):e331-4. doi: 10.2106/JBJS.L.00031.
- RIPO Register, <https://ripo.cineca.it>, Annual Report 2012
- Sehatzadeh S, Kaulback K, Levin L.. Metal-on-metal hip resurfacing arthroplasty: an analysis of safety and revision rates. *Ont Health Technol Assess Ser.* 2012;12(19):1-63. Epub 2012 Aug 1.
- Shimmin AJ, Barre JV. Comparison of functional results of hip resurfacing and total hip replacement: a review of the literature. *Orthop Clin N Am* (2011); 42:143-151
- Shrader MW, Bhowmik-Stoker M, Jacofsky MC, Jacofsky DJ. Gait and stair function in total and resurfacing hip arthroplasty: a pilot study. *Clin Orthop Relat Res.* 2009 Jun;467(6):1476-84
- Siddiqui IA, Sabah SA, Satchithananda K, Lim AK, Henckel J, Skinner JA, Hart AJ. Cross-sectional imaging of the metal-on-metal hip prosthesis: the London ultrasound protocol. *Clin Radiol.* 2013 Aug;68(8):e472-8. doi: 10.1016/j.crad.2013.02.003. Epub 2013 May 17.
- Sidiginamale RP, Joyce TJ, Lord JK, Jefferson R, Blain PG, Nargol AV, Langton DJ. Blood metal ion testing is an effective screening tool to identify poorly performing metal-on-metal bearing surfaces. *Bone Joint Res.* 2013 May 16;2(5):84-95
- Siemiatycki, J.; Dewar, R.; Nadon, L.; Gerin, M. Occupational risk factors for bladder cancer: results from a case-control study in Montreal, Quebec, Canada. *Am. J Epidemiol.* 1994, 140 (12), 1061-1080.
- Sikes CV, Lai LP, Schreiber M, Mont MA, Jinnah RH, Seyler TM (2008) Instability after total hip arthroplasty: treatment with large femoral heads vs constrained liners. *J Arthroplasty* 23(7 Suppl):59-63
- Smith AJ, Dieppe P, Porter M, Blom AW; National Joint Registry of England and Wales. Risk of cancer in first seven years after metal-on-metal hip replacement compared with other bearings and general population: linkage study between the National Joint Registry of England and Wales and hospital episode statistics. *BMJ.* 2012 Apr 3;344:e2383. doi: 10.1136/bmj.e2383.
- Smolders JMH, Bisseling P, Hol A, Van Der Straeten C, Schreurs BW, van Susante JLC. Metal ion interpretation in resurfacing versus conventional hip arthroplasty and in whole blood versus serum. How should we interpret metal ion data? *Hip Int.* 2011;21:587-595.
- Smolders JM, Hol A, van Susante JL. Metal ion trend may be more predictive for malfunctioning metal-on-metal implants than a single measurement. *Hip Int.* 2013 Oct 28;23(5):434-40
- Sotos JG, Tower SS. Systemic disease after hip replacement: aeromedical implications of arthroprosthetic cobaltism. *Aviat Space Environ Med.* 2013 Mar;84(3):242-5.
- Steiger de RN, Miller LN, Prosser GH, Graves SE, Davidson DC, Stanford TE, Poor outcome of revised resurfacing hip arthroplasty. 397 cases from the Australian joint replacement registry. *Acta Orthop.* 2010;81(1):72-76
- Thomas MS, Wimhurst JA, Nolan JF, Toms AP. Imaging Metal-on-Metal Hip Replacements: the Norwich Experience. *HSS J.* 2013 Oct;9(3):247-256. Epub 2013 Aug 24.

- Toms AP, Marshall TJ, Cahir J, Darrah C, Nolan J, Donell ST, Barker T, Tucker JK. MRI of early symptomatic metal-on-metal total hip arthroplasty: a retrospective review of radiological findings in 20 hips. *Clin Radiol*. 2008 Jan;63(1):49-58. Epub 2007 Oct 24.
- Tower SS. Arthroprosthetic cobaltism: neurological and cardiac manifestations in two patients with Metal-on-Metal arthroplasty: a case report. *J Bone Joint Surg Am*. 2010;92:2847-2851.
- Treacy RB, McBryde CW, Shears E, Pynsent PB (2011) Birmingham hip resurfacing: a minimum follow-up of ten years. *J Bone Joint Surg Br* 93(1):27-33
- Van Der Straeten C, Grammatopoulos G, Gill HS, Calistri A, Campbell P, De Smet KA. The 2012 Otto Aufranc Award: The interpretation of Metal Ion Levels in Unilateral and Bilateral Hip Resurfacing. *Clinical Orthopedics and Related Research Vol 471, Issue 2 (2013): 377-85*.
- Van Der Straeten C, Metal ions from Metal-on-Metal Hip Arthroplasties. *Orthopädie im Profil*, 8. Jahrgang. April 2012, 20-21
- Van Der Straeten C, Murray D. Interpretation and Use of Data from Arthroplasty Registers. *Orthopädie im Profil*, 7. Jahrgang. April 2011
- Van Der Straeten C. Researchers set safe upper limit metal ion levels for Metal-on-Metal hip resurfacings. *Orthopedics Today*. July 2012
- Van der Weegen H, Hoekstra HJ, Sijbesma T, Bos E, Schemitsch EH, Poolman RW. Survival of Metal-on-Metal hip resurfacing arthroplasty. A systematic review of the literature. *J Bone Joint Surg [Br]* 2011;93-B:298-306.
- van der Weegen W, Sijbesma T, Hoekstra HJ, Brakel K, Pilot P, Nelissen RG. Treatment of Pseudotumors After Metal-on-Metal Hip Resurfacing Based on Magnetic Resonance Imaging, Metal Ion Levels and Symptoms. *J Arthroplasty*. 2013 Jul 18. pii: S0883-5403(13)00434-8. doi: 10.1016/j.arth.2013.06.021. [Epub ahead of print]
- van der Weegen W, Smolders JM, Sijbesma T, Hoekstra HJ, Brakel K, van Susante JL. High incidence of pseudotumours after hip resurfacing even in low risk patients; results from an intensified MRI screening protocol. *Hip Int*. 2013 May-Jun;23(3):243-9. doi: 10.5301/hipint.5000004. Epub 2012 Dec 11.
- van Lingen CP, Ettema HB, Timmer JR, de Jong G, Verheyen CC. Clinical manifestations in ten patients with asymptomatic metal-on-metal hip arthroplasty with very high cobalt levels. *Hip Int*. 2013 Oct 28;23(5):441-4
- Van Quickenborne D, De Smet KA, Van Der Straeten C. Gehoorverlies bij een bilaterale heupresurfacing. *Tijdschrift voor Geneeskunde* November 2012.
- Vendittoli PA, Amzica T, Roy AG, Lusignan D, Girard J, Lavigne M (2011) Metal Ion release with large-diameter Metal-on-Metal hip arthroplasty. *J Arthroplasty* 26(2):282-288
- Vendittoli PA, Ganapathi, Roy AG, Lusignan D, Lavigne M. A comparison of clinical results of hip resurfacing arthroplasty and 28 mm metal on metal total hip arthroplasty: a randomised trial with 3-6 years follow-up. *Hip Int* 2010; 20 (01): 1-13
- Vendittoli PA, Mottard S, Roy AG, Dupont C, Lavigne M: Chromium and cobalt ion release following the Durom high carbon content, forged Metal-on-Metal surface replacement of the hip. *J Bone Joint Surg Br* 2007;89:441-448
- Visuri T, Borg H, Pulkkinen P, Paavolainen P, Pukkala E (2010) A retrospective comparative study of mortality and causes of death among patients with Metal-on-Metal and metal-on-polyethylene total hip prostheses in primary osteoarthritis after a long-term follow-up. *BMC Musculoskelet Disord* 11:78
- Visuri T, Pukkala E, Pulkkinen P, Paavolainen P (2003) Decreased cancer risk in patients who have been operated on with total hip and knee arthroplasty for primary osteoarthritis: a meta-analysis of 6 Nordic cohorts with 73 000 patients. *Acta Orthop Scand* 74(3):351-360
- Visuri T, Pulkkinen P, Paavolainen P, Pukkala E. Cancer risk is not increased after conventional hip arthroplasty. *Acta Orthop*. 2010 Feb;81(1):77-81. doi: 10.3109/17453671003667150

- Visuri TI, Pukkala E, Pulkkinen P, Paavolainen P. Cancer incidence and causes of death among total hip replacement patients: a review based on Nordic cohorts with a special emphasis on metal-on-metal bearings. *Proc Inst Mech Eng H*. 2006 Feb;220(2):399-407.
- Wagner P, Olsson H, Lidgren L, Robertsson O, Ranstam J (2011) Increased cancer risks among arthroplasty patients: 30 year follow-up of the Swedish Knee Arthroplasty Register. *Eur J Cancer* 47(7):1061-1071
- Warheit, D. B.; Webb, T. R.; Reed, K. L.; Frerichs, S.; Sayes, C. M. Pulmonary toxicity study in rats with three forms of ultrafine-TiO₂ particles: differential responses related to surface properties. *Toxicology* 2007, 230 (1), 90-104.
- Warheit, D. B.; Webb, T. R.; Sayes, C. M.; Colvin, V. L.; Reed, K. L. Pulmonary instillation studies with nanoscale TiO₂ rods and dots in rats: toxicity is not dependent upon particle size and surface area. *Toxicol. Sci.* 2006, 91 (1), 227-236.
- Wiley KF, Ding K, Stoner JA, Teague DC, Yousuf KM. Incidence of pseudotumor and acute lymphocytic vasculitis associated lesion (ALVAL) reactions in metal-on-metal hip articulations: a meta-analysis. *J Arthroplasty*. 2013 Aug;28(7):1238-45. doi: 10.1016/j.arth.2013.03.027. Epub 2013 May 6.
- Willert HG, Buchhorn GH, Fayyazi A, Flury R, Windler M, Koster G, Lohmann CH (2005) Metal-on-metal bearings and hypersensitivity in patients with artificial hip joints. A clinical and histomorphological study. *J Bone Joint Surg Am* 87(1):28-36
- Willert HG, Buchhorn GH, Semlitsch M (1993) Particle disease due to wear of metal alloys. Findings from retrieval studies. In: *Biological, Material and Mechanical considerations of Joint Replacement*. Ed. Morrey BF, Raven Press Ltd., New York. pp129-146.
- Willert HG, Semlitsch M (1977) Reactions of the articular capsule to wear products of artificial joint prostheses. *J Biomed Mater Res* 11(2):157-164
- Williams DH, Greidanus NV, Masri BA, Duncan CP, Garbuz DS (2011) Prevalence of pseudotumor in asymptomatic patients after Metal-on-Metal hip arthroplasty. *J Bone Joint Surg Am* 93(23):2164-2171
- Wyles CC, Van Demark RE 3rd, Sierra RJ, Trousdale RT. High Rate of Infection After Aseptic Revision of Failed Metal-on-Metal Total Hip Arthroplasty. *Clin Orthop Relat Res*. 2013 Jul 12. [Epub ahead of print]
- Yang J, Shen B, Zhou Z, Pei F, Kang P (2011) Changes in cobalt and chromium levels after Metal-on-Metal hip resurfacing in young, active Chinese patients. *J Arthroplasty* 26(1):65-70
- Zagra L, Anasetti F, Bianchi L, Licari V, Giacometti Ceroni R. No Difference in Gait Recovery After THA With Different Head Diameters: A Prospective Randomized Study. *Clin Orthop Relat Res*. 2013
- Zeng Y, Feng W. Metal allergy in patients with total hip replacement: a review. *J Int Med Res*. 2013 Apr;41(2):247-52. doi: 10.1177/0300060513476583. Epub 2013 Feb 22.
- Zenz P, Stiehl JB, Knechtel H, Titzer-Hochmaier G, Schwagerl W (2009) Ten-year follow-up of the non-porous Allofit cementless acetabular component. *J Bone Joint Surg Br* 91(11):1443-1447
- Ziaee H, Daniel J, Datta AK, Blunt S, McMinn DJ (2007) Transplacental transfer of cobalt and chromium in patients with Metal-on-Metal hip arthroplasty: a controlled study. *J Bone Joint Surg Br* 89(3):301-305
- Zywiell MG, Brandt JM, Overgaard CB, Cheung AC, Turgeon TR, Syed KA. Fatal cardiomyopathy after revision total hip replacement for fracture of a ceramic liner. *Bone Joint J*. 2013 Jan;95-B(1):31-7. doi: 10.1302/0301-620X.95B1.30060.

Appendix 1: Detailed description of Metal-on-Metal implants

1.1. Composition of Metal-on-Metal implants

Several different metal alloys are used in Metal-on-Metal (MoM) implants. The bearing surface itself is mostly made from CoCrMo-alloys. They contain Chromium 26.5–30%, Molybdenum 4.5–7.0%, Carbon 0.05–0.35%, Nickel <1%, Iron <1%, Manganese <1%, and Silicon <1%. Low carbon alloys contain around 0.05% Carbon, high carbon alloys around 0.20%. The exact composition of the alloys is specified in several international standards, which are summarised in ISO-21534. The alloys are manufactured either wrought, cast, annealed and sometimes heat-treated. They can be additionally coated with Chromium-Nitride (CrN), Chromium-Carbon-Nitride (CrCN), Titanium-Nitride (TiN) or Titanium-Niobium-Nitride (TiNbN). For allergy patients, also coated Ti-alloys are used as bearing articulations.

The metal shell of modular cups and the stem are typically made of Ti-alloys in different compositions. In addition to Ti, these alloys may contain, for example, Al, V, Mo, Si, and Fe in varying percentages. These components are sometimes coated with hydroxyapatite (HA) with the aim for a better bone in- or on-growth.

Monobloc cups are always made from CoCr-alloys. The outer surface is sometimes coated with a Plasma sprayed Titanium coating for the aim of better bone in- or on-growth.

1.2. Types of Metal-on-Metal implants

The first generation of Metal-on-Metal (MoM) hip prostheses is attributed to Philip Wiles in 1938. In the five decades after this innovation, several surgeons (Haboush, McKee, Lord, Ring, Huggler, Müller) adopted MoM bearing couples, but none of these designs was really successful in a high percentage of patients.

Two different design categories of MoM bearing articulations have been used more or less successfully since 1998, the start of the second generation (tighter manufacturing tolerances, better alloys), of MoM implants for total hip arthroplasty:

(1) Modular MoM implants

(a) Small-head THA: Modular metal head on a hip stem with a modular metal insert in a metal socket with a head diameter of less than 36 mm (Fig. 1)

(b) Large-head THA: Modular metal head on a hip stem with a metal cup, with a head diameter of 36 mm or more (Fig. 2). The metal cup could either be:

(b1) Modular

(b2) Monobloc

(2) Resurfacing (HRA): Metal resurfacing head with a monobloc metal cup (Fig. 3)

Examples of MoM hip implants are presented in Figure 1. The choice of the components is not related to the problems observed with certain Metal-on-Metal hip bearing articulations. Sizes are only examples and represent typical measures.




Figure 1: Contemporary designs of Metal-on-Metal hip joint articulations. They can be grouped into two different categories with subgroups: Category 1a: A&E&I, Category 1b1: B&F&I; Category 1b2: C&G&I; Category 2: D&H. (Source: M. Morlock)

In detail, the components are:

- (A) Metal socket with a modular metal insert in a plastic liner (diameter 28mm). The outside of the socket is made of Ti-alloy whereas the bearing surface is made from CoCr-alloy
- (B) Metal socket (Ti-alloy) with a modular metal insert made from CoCr-alloy (diameter 36mm)
- (C) Monobloc metal cup made of CoCr-alloy coated with TiNbN (diameter 42mm)
- (D) Monobloc metal cup made of CoCr-alloy (diameter 54mm)
- (E) Modular metal head made of CoCr-alloy (diameter 28mm)
- (F) Modular metal head made of CoCr-alloy (diameter 36mm)
- (G) Modular metal head made of CoCr-alloy coated with TiNbN (diameter 42mm)
- (H) Monobloc resurfacing head made of CoCr-alloy (diameter 54mm)
- (I) Modular uncemented hip stem made of Ti-alloy.

Category 1a – Small-head modular MoM implants

In 1998, the time of the second generation MoM bearings started (Metasul™, Sulzer, Switzerland). This design with heads of 28mm and 32mm diameter achieved similar or better clinical success as other bearing materials and is still used (Fig. 2). Newer Category 1 MoM designs are quite similar but omit the plastic (polyethylene) sandwich. Category 1 designs are typically used in conjunction with a modular uncemented hip stem and a modular uncemented hip socket both made from Ti-alloys.




Figure 2: Components of contemporary Category 1a MoM bearing articulations (Source: M.Morlock):

- (A) Backside of an uncemented hip socket with porous titanium surface for bone on- or ingrowth and screw holes for additional fixation
- (B) Frontside of the same socket with taper for fixation of the bearing insert
- (C) Metal CoCr-alloy bearing insert for a metal head with a diameter of 32mm
- (D) Metal CoCr-alloy head with a diameter of 32mm.

Category 1b - Large-head modular MoM implants

The use of modular metal heads with 36mm diameter and larger is rather recent. If the head diameter is getting too large, modular cups are not possible anymore and monobloc metal cups are required. These are the same cups as used with resurfacing (category 3).

Category 1b1 Large-head MoM implants with modular metal cup

These designs are similar to category 1a designs with exception of the larger diameter. The most common diameters range between 36 and 44mm (Fig 3).



Figure 3: The two articulating components of contemporary Category 1b1 MoM bearing articulations with a diameter of 36mm. The CoCr-alloy metal cup liner has a thinner wall thickness as the 32mm diameter liner shown in Figure 2 and such fits in the same uncemented hip socket. (Source: M.Morlock)

Category 1b2 Large-head MoM implant with monobloc cup

This is a rather new philosophy and part of the third generation (engineered bearings with larger diameters and monobloc metal cups) of MoM bearings (Fig. 1 (C), (D) & (G)). It originates from the necessity for a revision option after failure of the femoral component (e.g. femoral neck fracture) in hip resurfacing arthroplasty and was introduced together with the revival of resurfacing arthroplasty around 1995. The large-head MoM option was promoted for well-fixed monobloc metal cups and allowed to revise the femoral side alone. Since the approval of resurfacing implants was delayed in some countries and the excitement for very large metal articulations was major, very large MoM implants opened a possibility to use very large metal articulations for primary surgery, since these heads were seen as a modification of the conventional systems of Categories 1 and 2a, which had proven good clinical success. Monobloc cups are always made from CoCr-alloys since this material is needed for the bearing surface (Fig 4). Category 2b designs are typically used in conjunction with a modular uncemented hip stem made from Ti-Alloy. The monobloc metal cups are implanted without cement.




Figure 4: Monobloc metal hip cup made from CoCr-alloy:
(A) Backside: Ingrowth surface
(B) Frontside: Bearing articulation. (Source: M.Morlock)

Category 2 Resurfacing

The revival of resurfacing arthroplasty – after the bad results with the Wagner resurfacing design in the 1970s and 1980s - was driven by Amstutz and McMinn around 1995. After several publications of good short- and midterm results, resurfacing became popular very quickly and many companies introduced own designs into the market (Fig. 5). The resurfacing head of Category 2 designs made from CoCr-alloys is cemented onto a reamed femoral head in most designs, the monobloc cup made from CoCr-alloy is used without cement in all designs.



Figure 5: Examples for different designs of hip resurfacing implants. (Source: M.Morlock)

Appendix 2: Selected recommendations for the management of patients with implanted MoM hip arthroplasties from national health authorities and scientific organisations

Medical device alert of the Medicines and Healthcare products Regulatory Agency on all Metal-on-Metal (MoM) hip replacements. MDA/2012/036 Issued: 25 June 2012

(www.mhra.gov.uk/Publications/Safetywarnings/MedicalDeviceAlerts/CON079157)

Issued: 25 June 2012 at 11:00

Ref: MDA/2012/036

Appendix

Management recommendations for patients with metal-on-metal hip replacement implants

| | MoM hip resurfacing (no stem) | | Stemmed MoM total hip replacements – femoral head diameter <36mm | | Stemmed MoM total hip replacements – femoral head diameter ≥36mm | | DePuy ASR™ hip replacements (all types) | |
|---|--|--|--|--|--|---|--|---|
| | Symptomatic patients | Asymptomatic patients | Symptomatic patients | Asymptomatic patients | Symptomatic patients | Asymptomatic patients | Symptomatic Patients | Asymptomatic patients |
| Patient follow-up | Annually for the life of the implant | According to local protocols | Annually for the life of the implant | According to local protocols | Annually for the life of the implant | Annually for the life of the implant | Annually for the life of the implant | Annually for the life of the implant |
| Imaging: MARS MRI or ultrasound | Recommended in all cases | No - unless concern exists for cohort or patient becomes symptomatic | Recommended in all cases | No - unless concern exists for cohort or patient becomes symptomatic | Recommended in all cases | Recommended if blood metal ion levels rising | Recommended in all cases | Recommended in all cases |
| 1 st blood metal ion level test | Yes | No - unless concern exists for cohort or patient becomes symptomatic | Yes | No - unless concern exists for cohort or patient becomes symptomatic | Yes | Yes | Yes | Yes |
| Results of 1 st blood metal ion level test | Blood metal ion level >7ppb indicates potential for soft tissue reaction | | Blood metal ion level >7ppb indicates potential for soft tissue reaction | | Blood metal ion level >7ppb indicates potential for soft tissue reaction | If blood metal ion level >7ppb then second blood test required 3 months later | Blood metal ion level >7ppb indicates potential for soft tissue reaction | If blood metal ion level >7ppb then second blood test required 3 months later |
| 2 nd blood metal ion level test | Yes - 3 months after 1 st blood test if result was >7ppb | | Yes - 3 months after 1 st blood test if result was >7ppb | | Yes - 3 months after 1 st blood test if result was >7ppb | Yes - 3 months after 1 st blood test if result was >7ppb | Yes - 3 months after 1 st blood test if result was >7ppb | Yes - 3 months after 1 st blood test if result was >7ppb |
| Results of 2 nd blood metal ion level test | Blood metal ion level >7ppb indicates potential for soft tissue reaction especially if greater than previously | | Blood metal ion level >7ppb indicates potential for soft tissue reaction especially if greater than previously | | Blood metal ion level >7ppb indicates potential for soft tissue reaction especially if greater than previously | If blood metal ion levels rising - further investigation required including imaging | Blood metal ion level >7ppb indicates potential for soft tissue reaction especially if greater than previously | Blood metal ion level rising indicates potential for soft tissue reaction |
| Consider need for revision | If imaging is abnormal and/or blood metal ion levels rising | | If imaging is abnormal and/or blood metal ion levels rising | | If imaging is abnormal and/or blood metal ion levels rising | If imaging is abnormal and/or blood metal ion levels rising | If imaging is abnormal and/or blood metal ion levels rising | If imaging is abnormal and/or blood metal ion levels rising |

Notes and guidance on next page

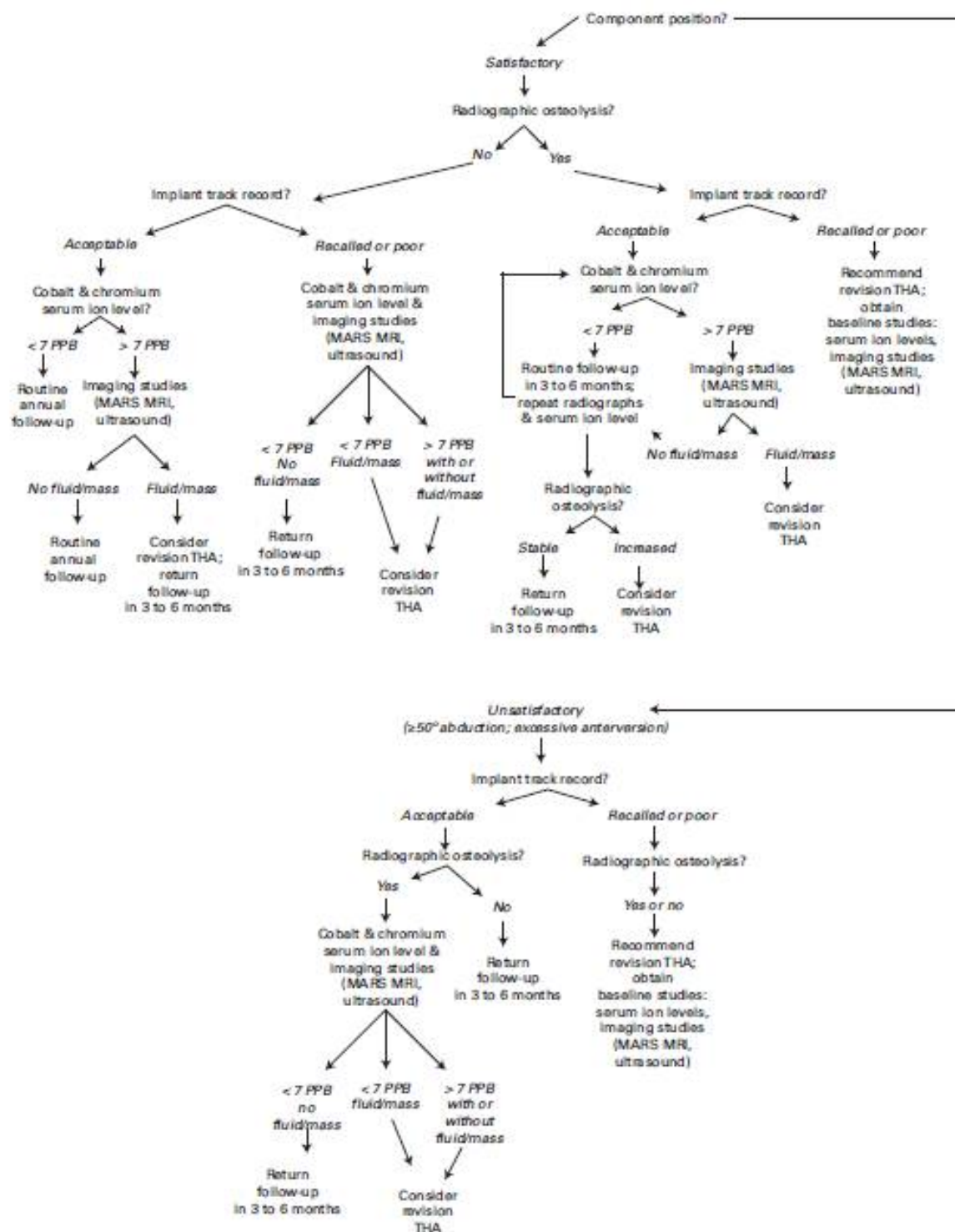


Fig. 1

An algorithm outlining the steps recommended for evaluating a patient who presents in follow-up after hip arthroplasty with an asymptomatic metal-on-metal articulation

Hip Society algorithmic approach to diagnosis and management of asymptomatic MoM hip arthroplasty patients (Lombardi et al. 2012)

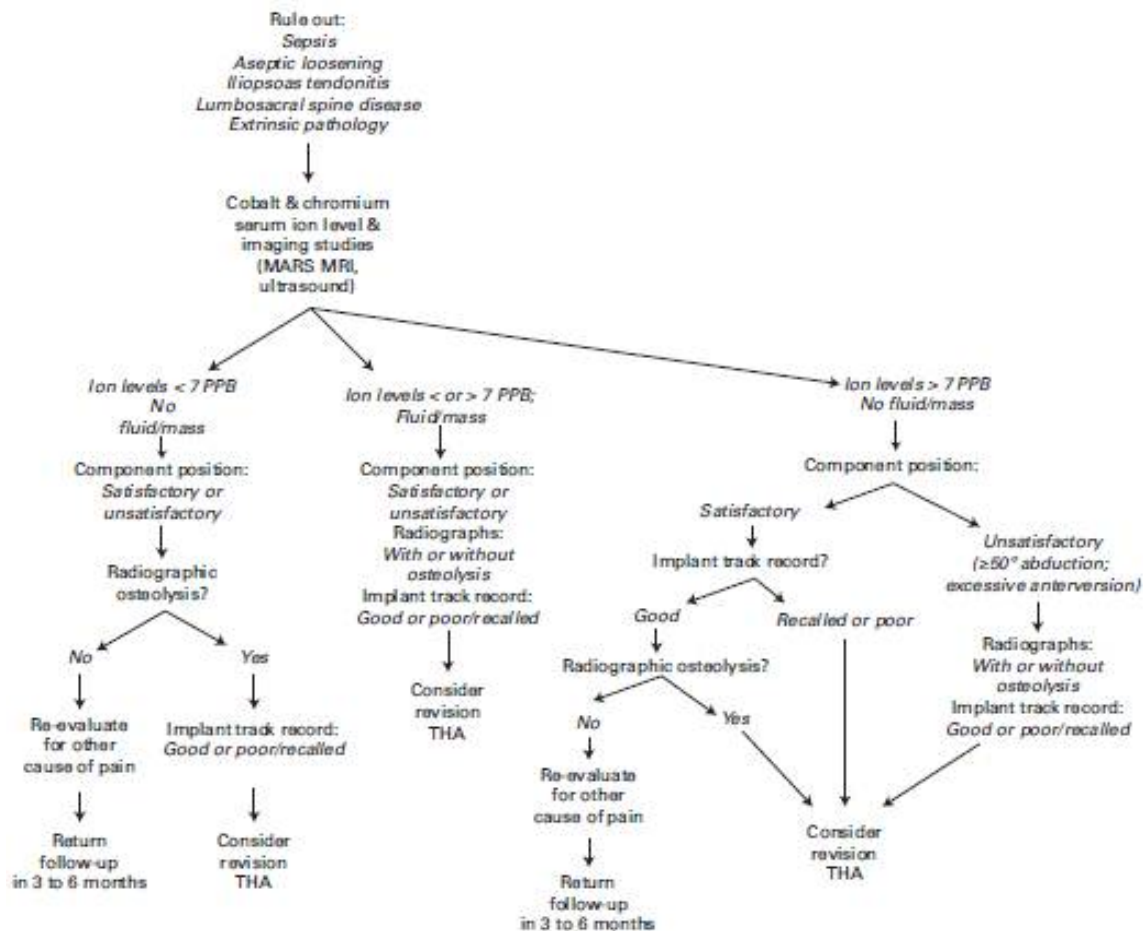


Fig. 2

An algorithm outlining the steps recommended for evaluating a patient who presents in follow-up after hip arthroplasty with a symptomatic metal-on-metal articulation

Hip Society algorithmic approach to diagnosis and management of symptomatic MoM hip arthroplasty patients (Lombardi et al. 2012)